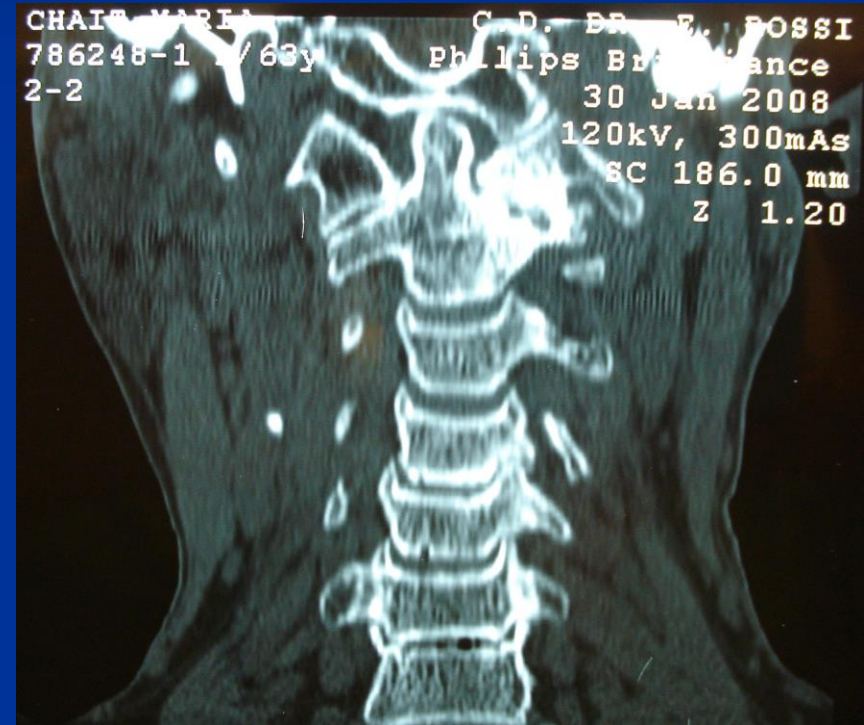

Doc. Ads. Dr. Gabriel Jungberg
División Neurocirugía Hospital
General “Ignacio Pirovano”

Facultad de Medicina
Universidad de Buenos Aires

Caso 1

- Paciente fem. 63a
- Dolor láterocervical sin irradiación a MS



CHAIT MARIA
786248-1 F/63y
80292-1
21.97 mm

C.D. D. F. ROSSI
Philips Brilliance 16
30 Jan 2008 12:46:07.0
120kV, 300mAs
SC 16.0 mm
SW 3.00 mm
Z 1.50

R

5 cm

CHAIT MARIA
786248-1 F/63y
80292-1
24.41 mm

C.D. D. F. ROSSI
Philips Brilliance 16
30 Jan 2008 12:46:07.0
120kV, 300mAs
SC 16.0 mm
SW 3.00 mm
Z 1.50

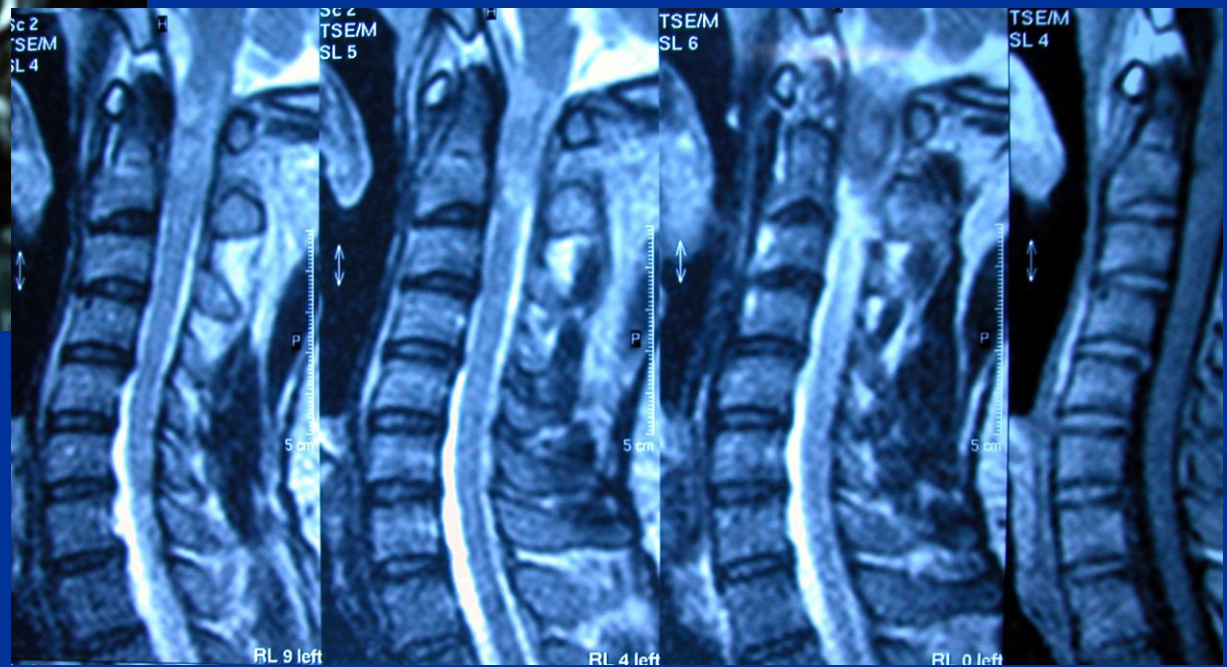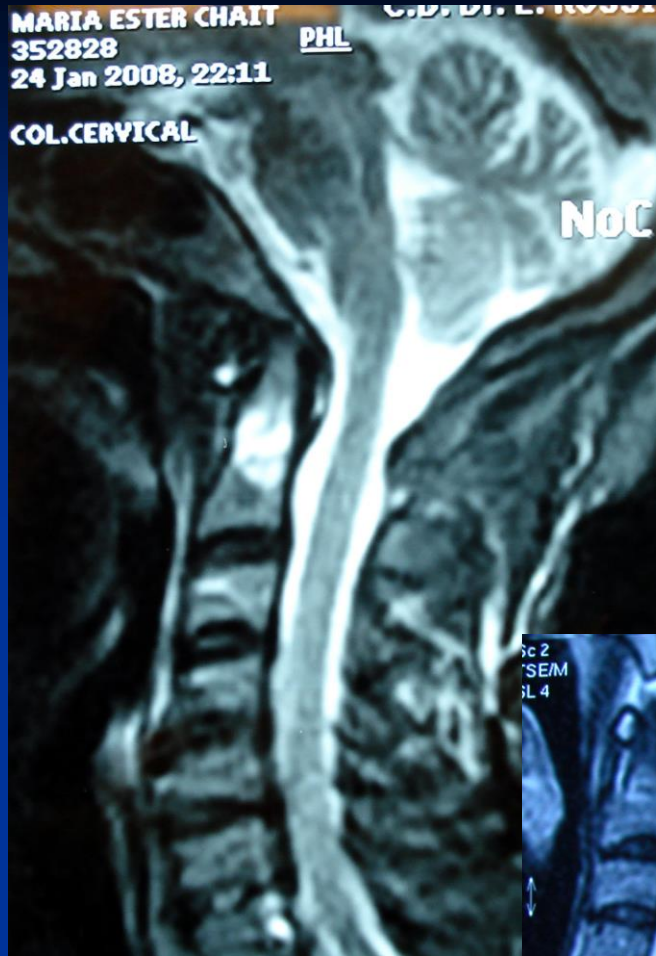
5 cm

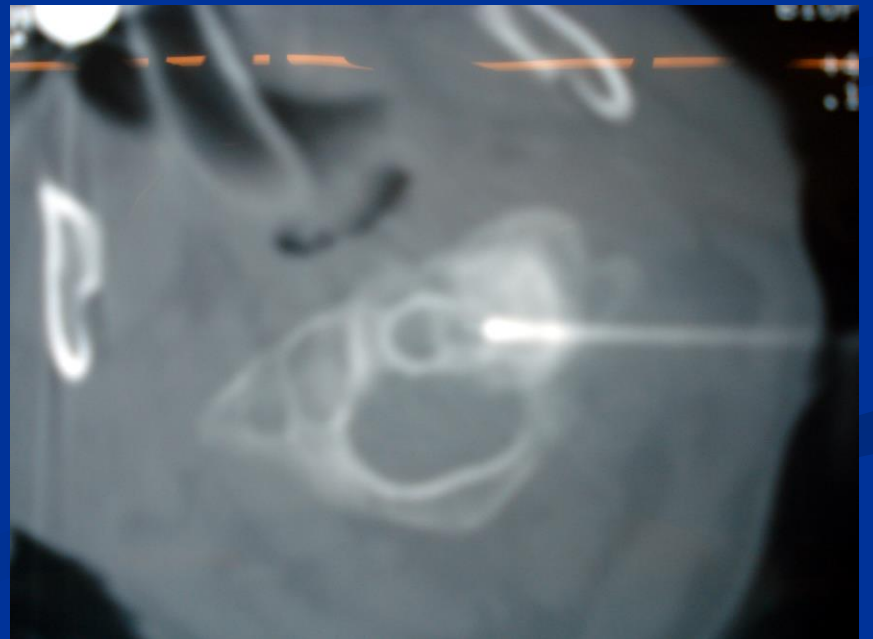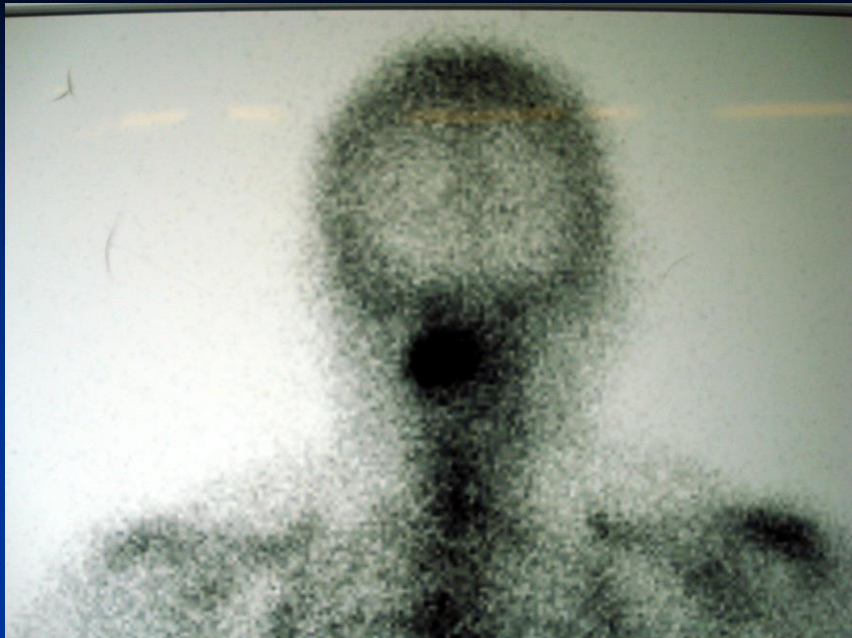
MARIA ESTER CHAIT
352828
24 Jan 2008, 22:11

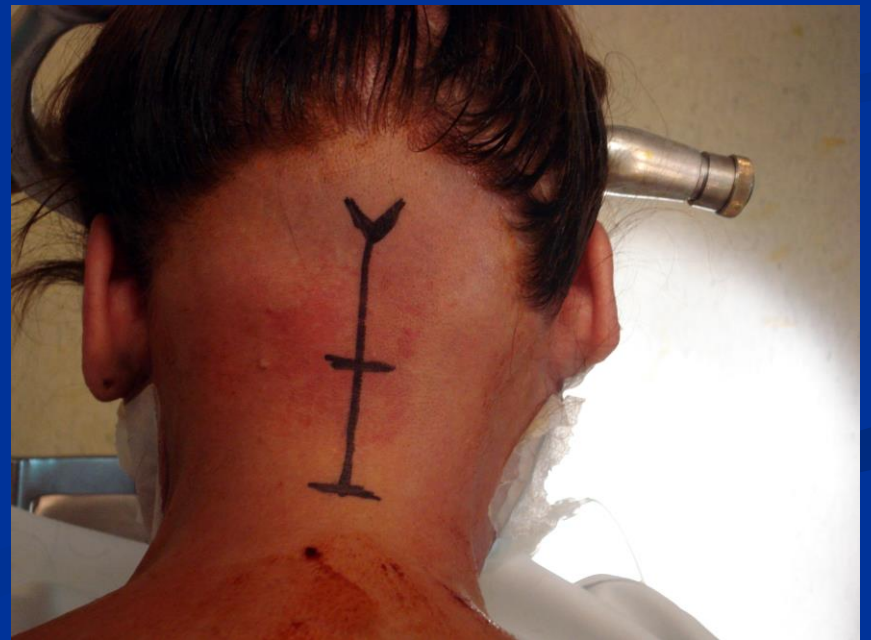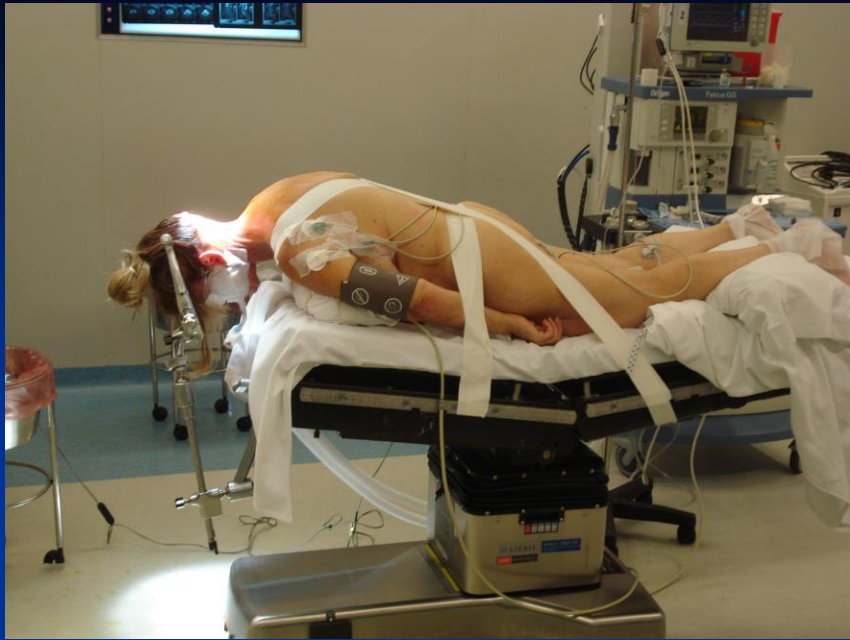PHL

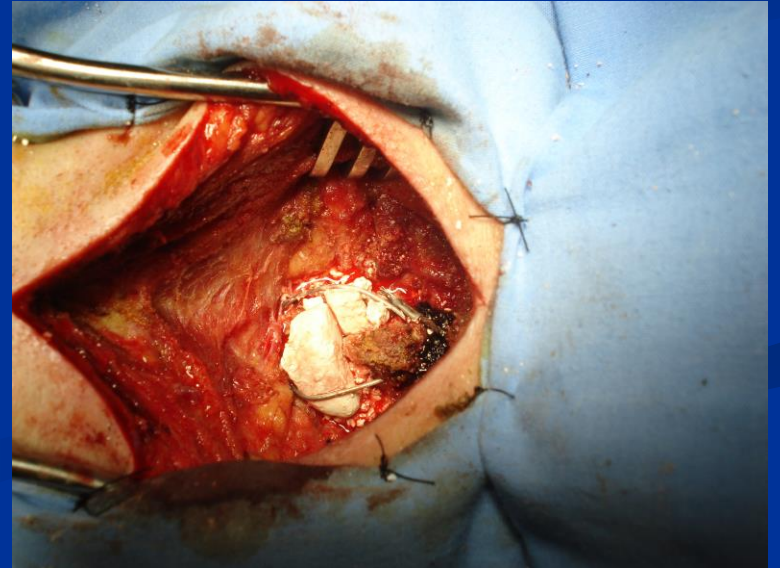
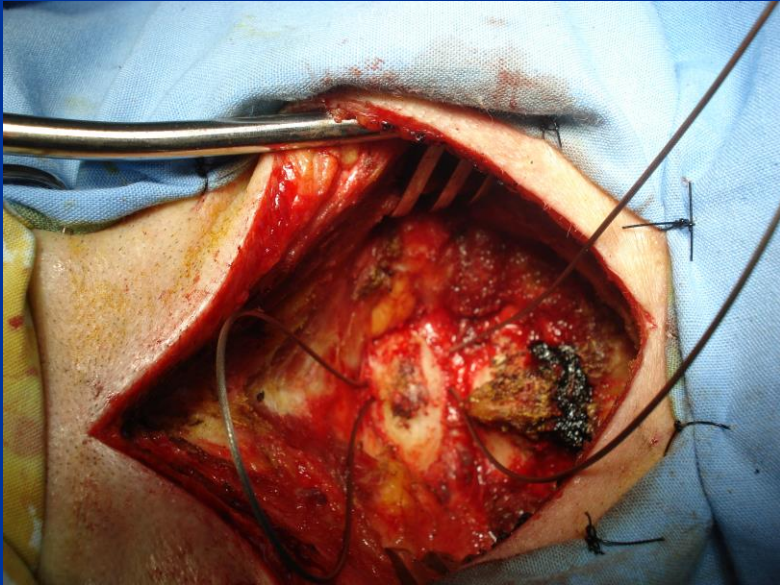
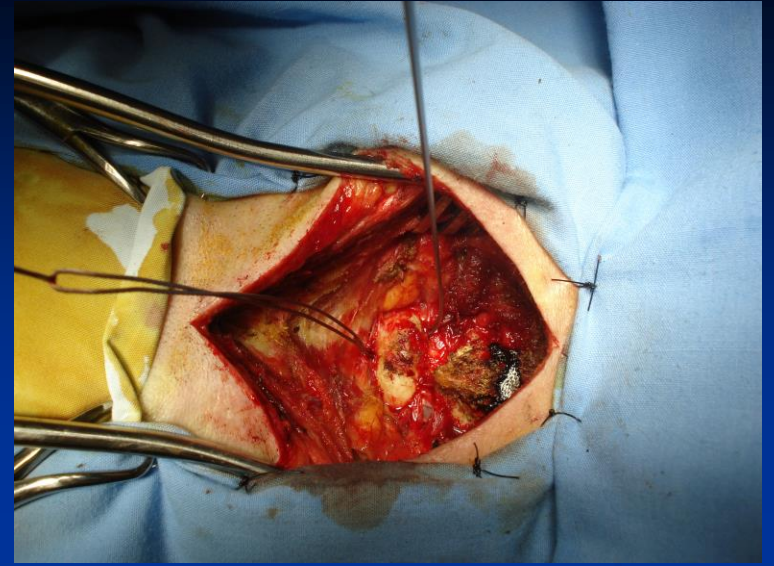
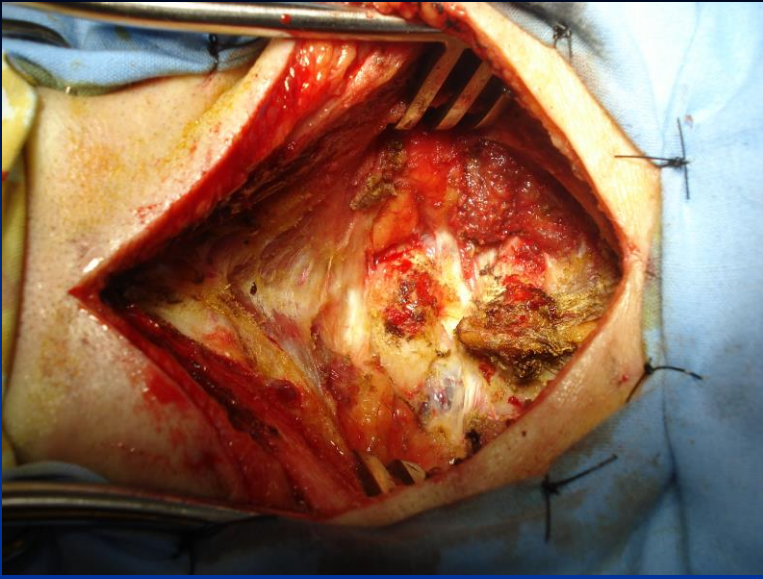
COL.CERVICAL

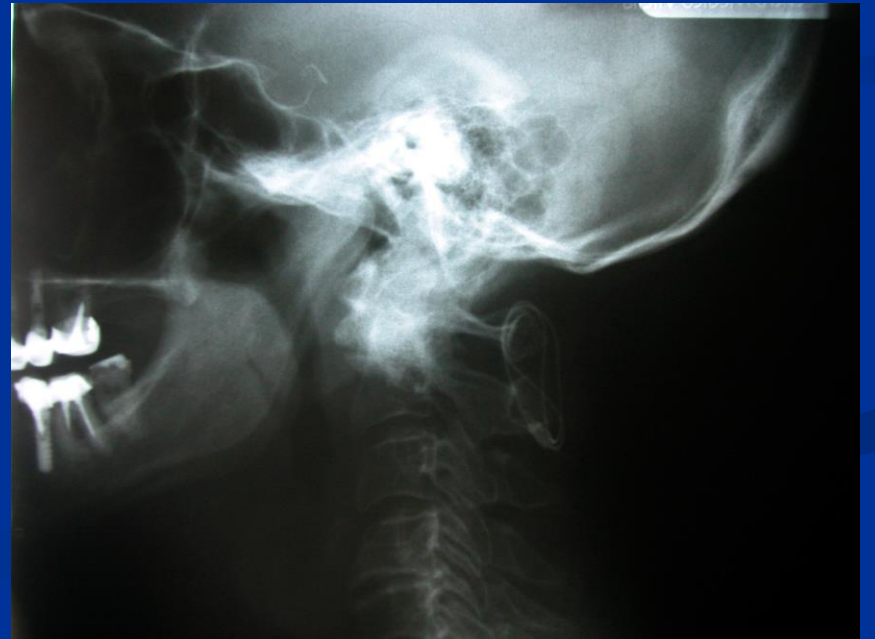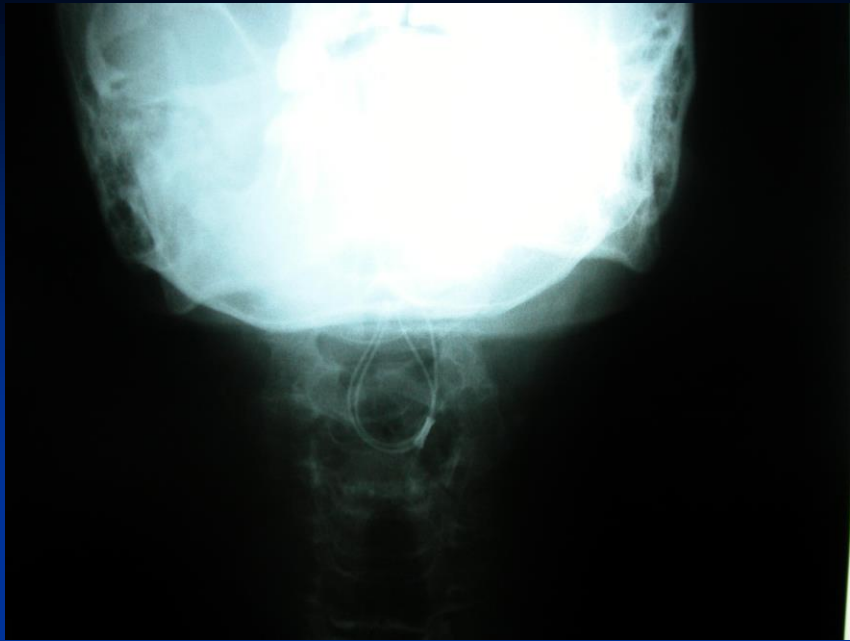
NoC







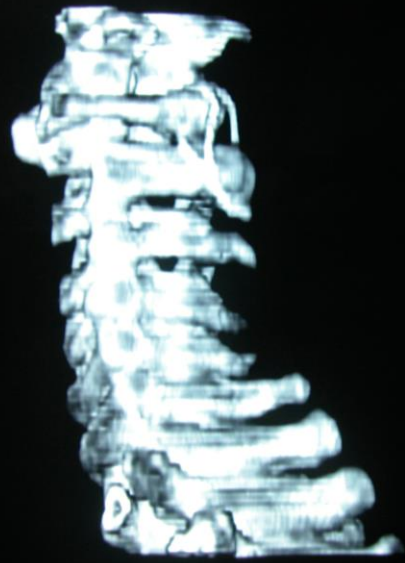




CHAT MARIA
9700 F
8500-3 3D

TCBA
Philips
3 Jul 2008
Z 1.71

AL



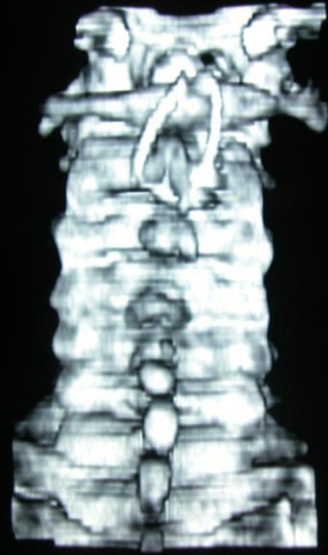20 cm

L P

CHAT MARIA
9700 F
8500-4 3D

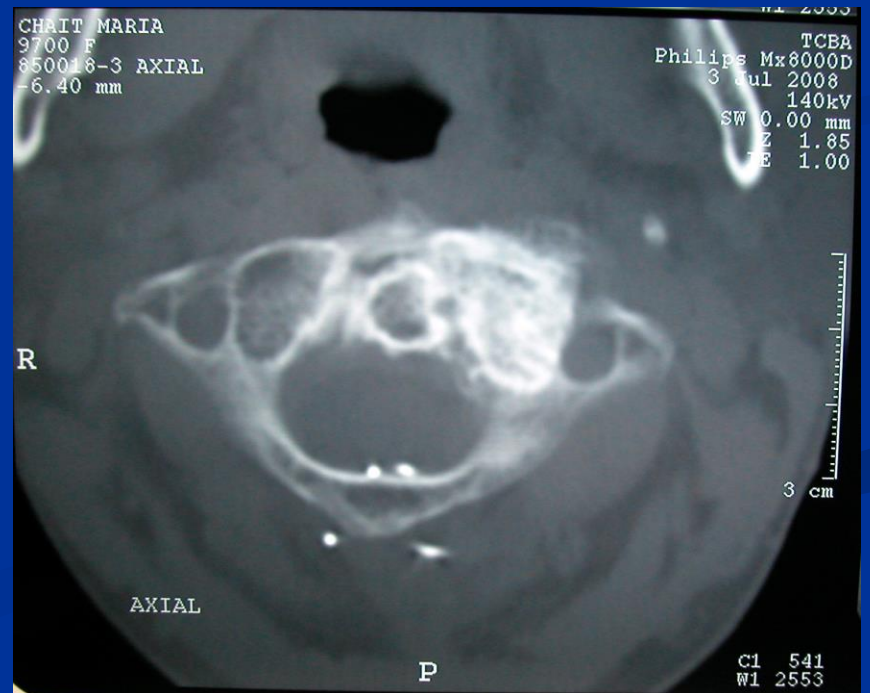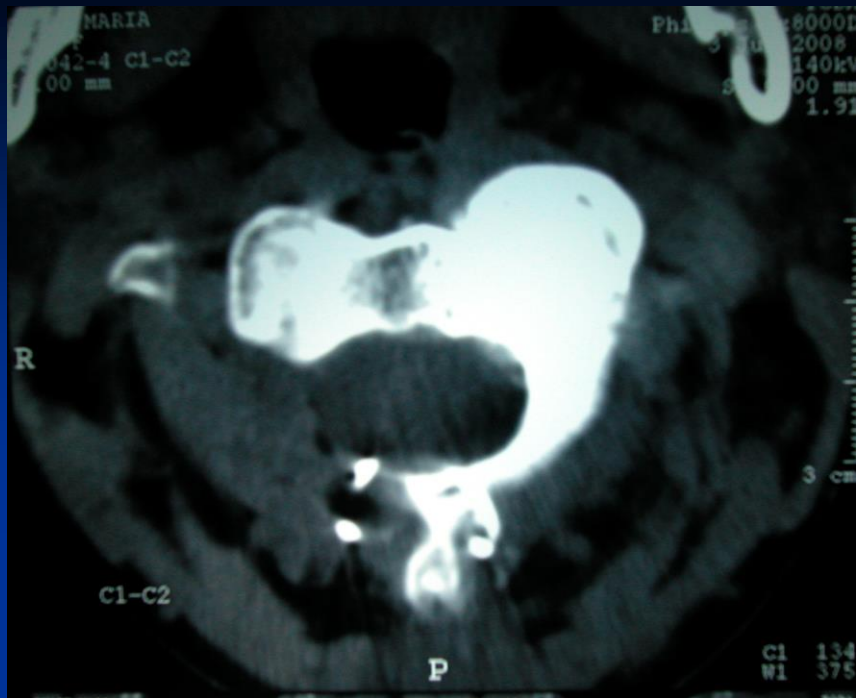TCBA
Philips
3 Jul 2008
Z 1.71

L



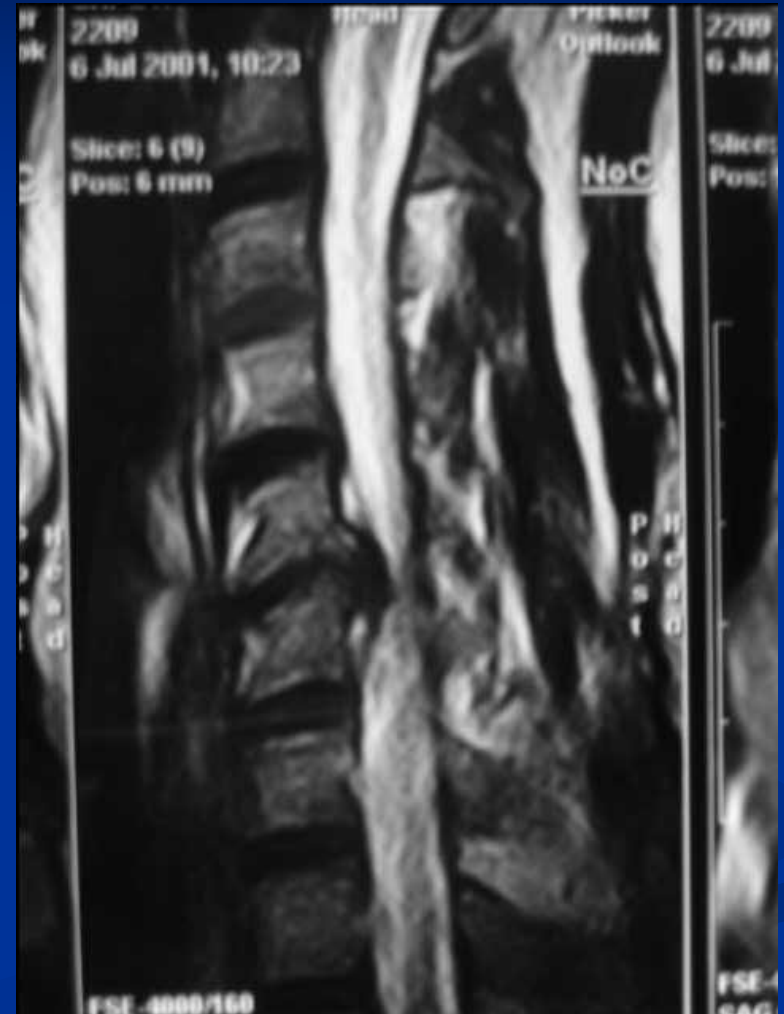20 cm

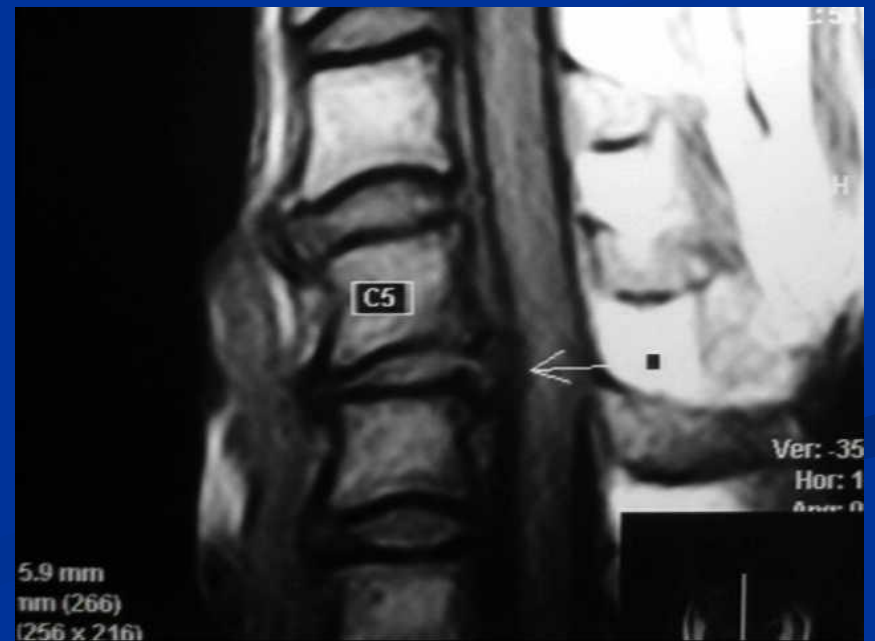
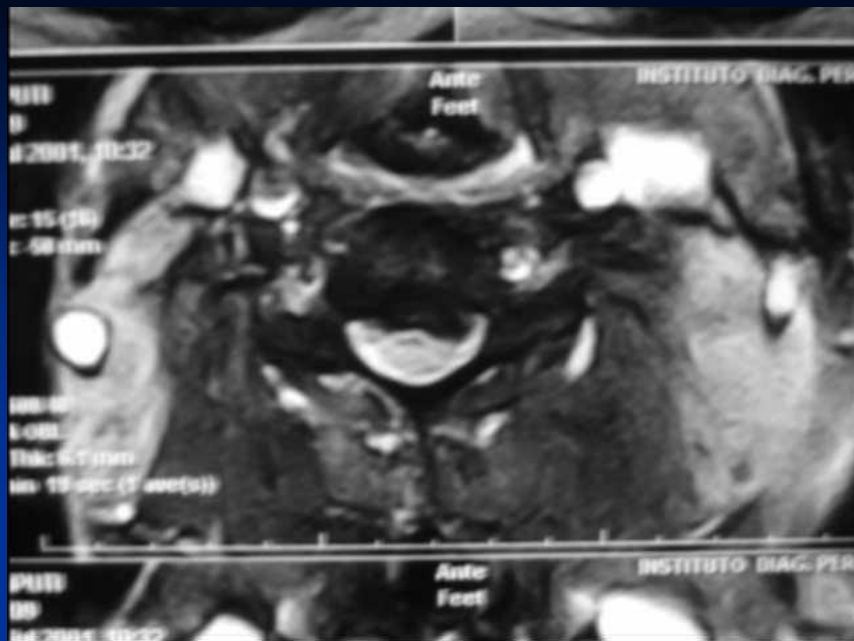
H
L P R

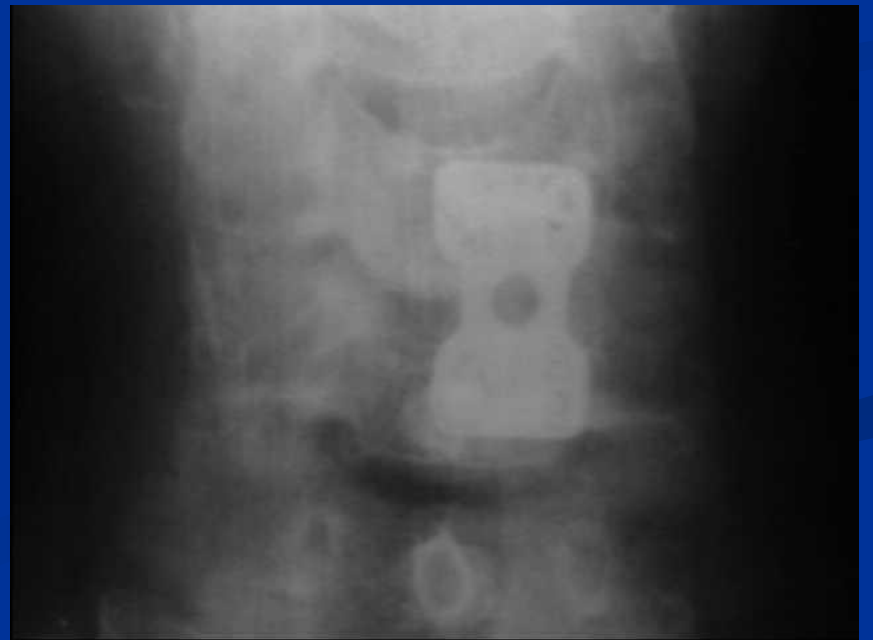
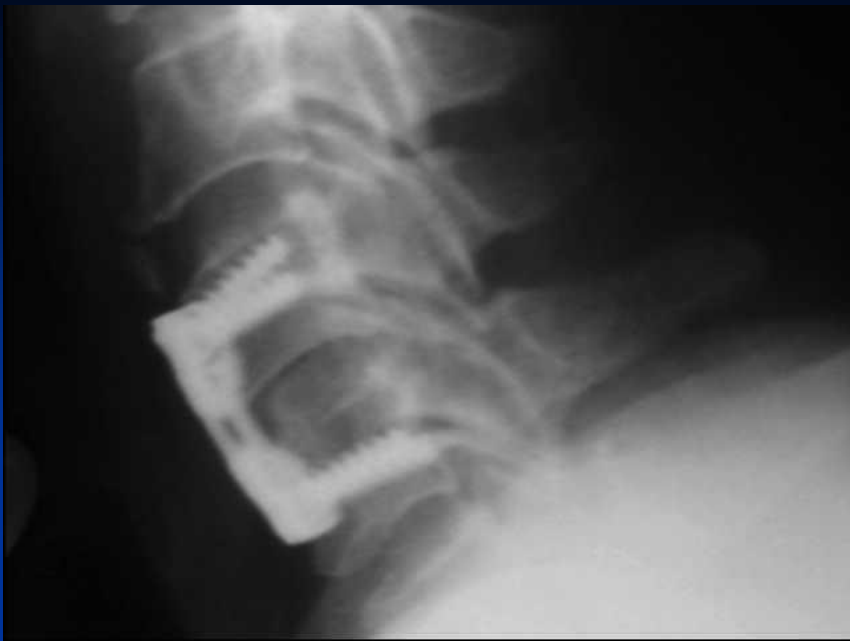
Caso 2

- Paciente de 52a, masc.
- Cervicobraquialgia derecha intratable, de 1 mes de evolución.
- Hipoestesia en 1ro. y 2do. dedos

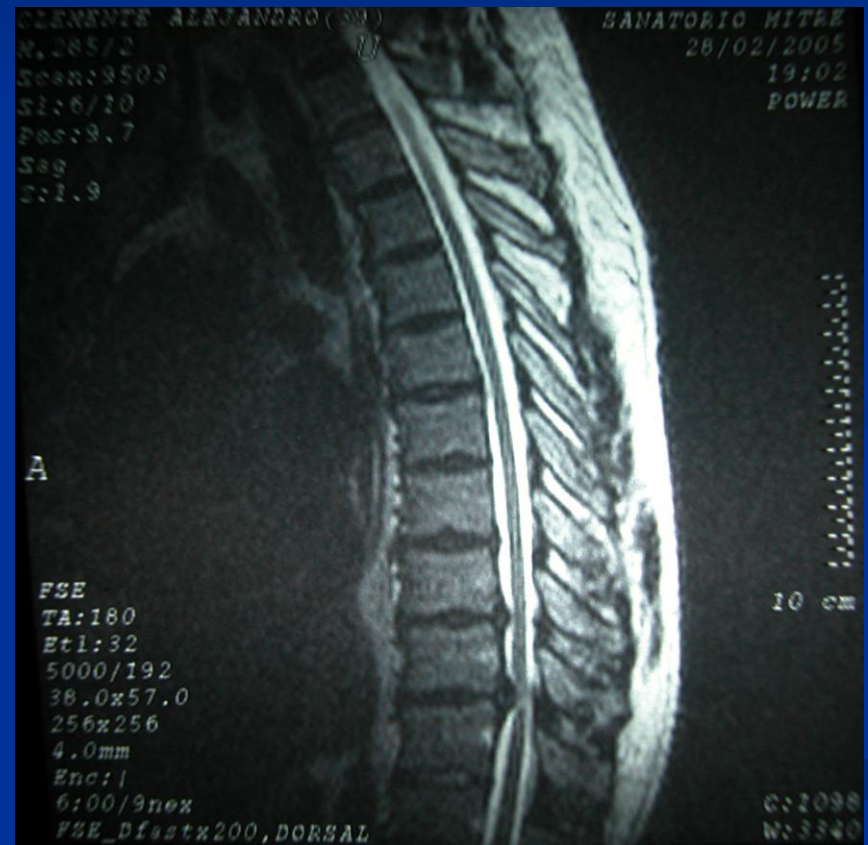

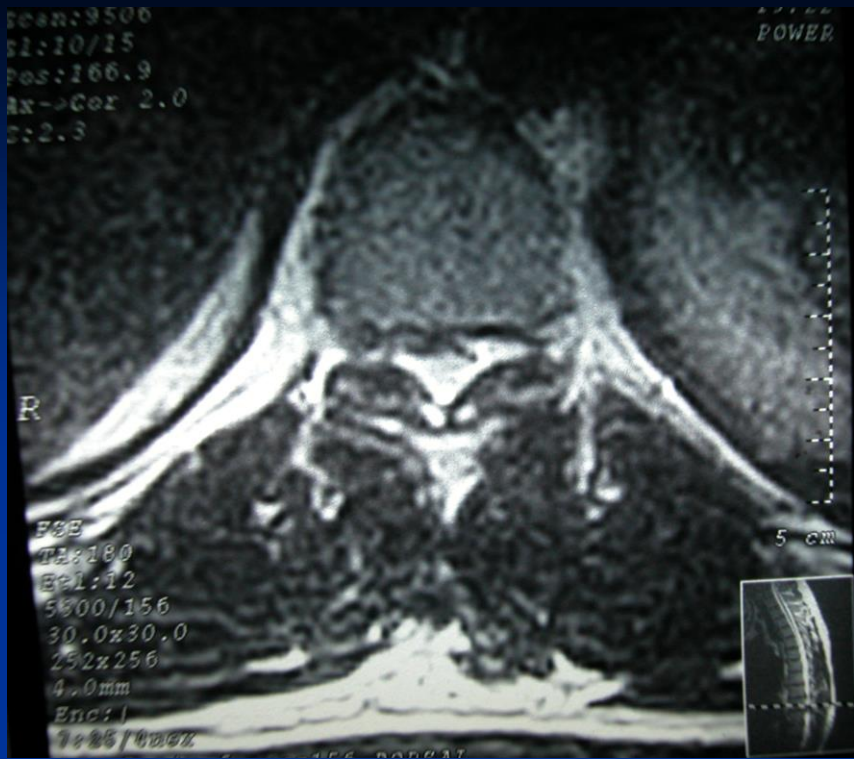



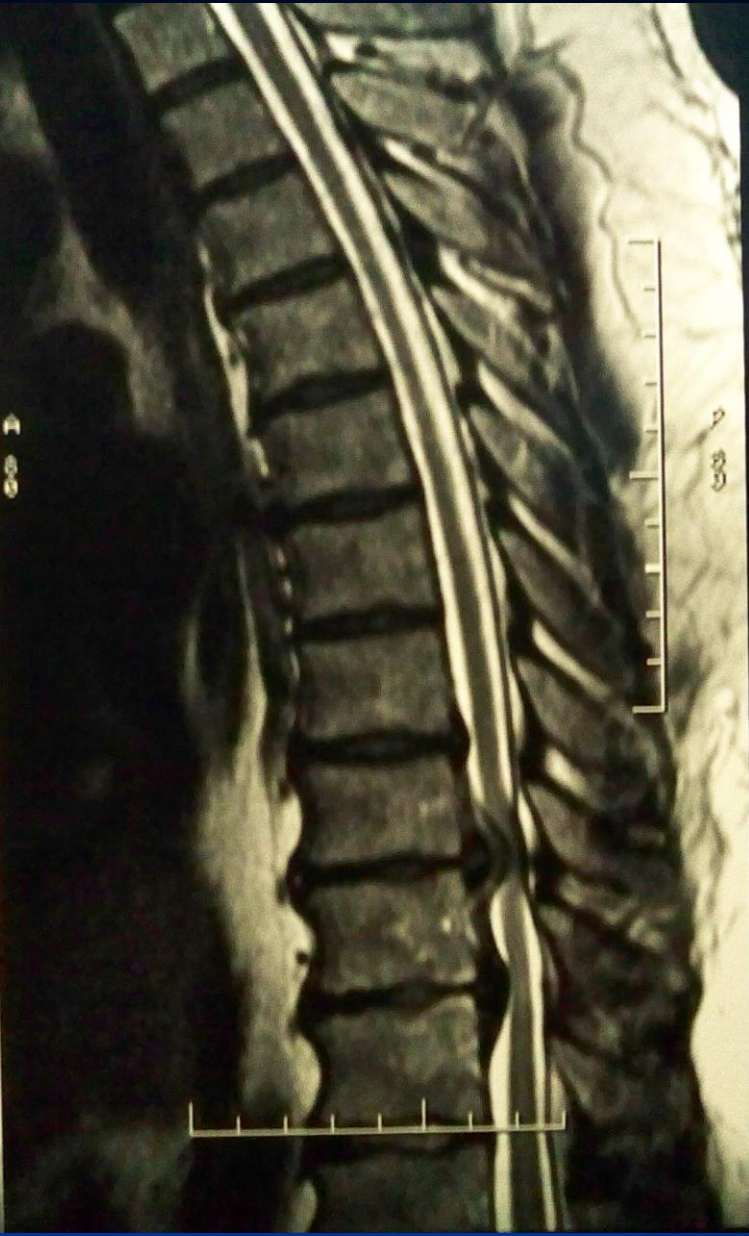
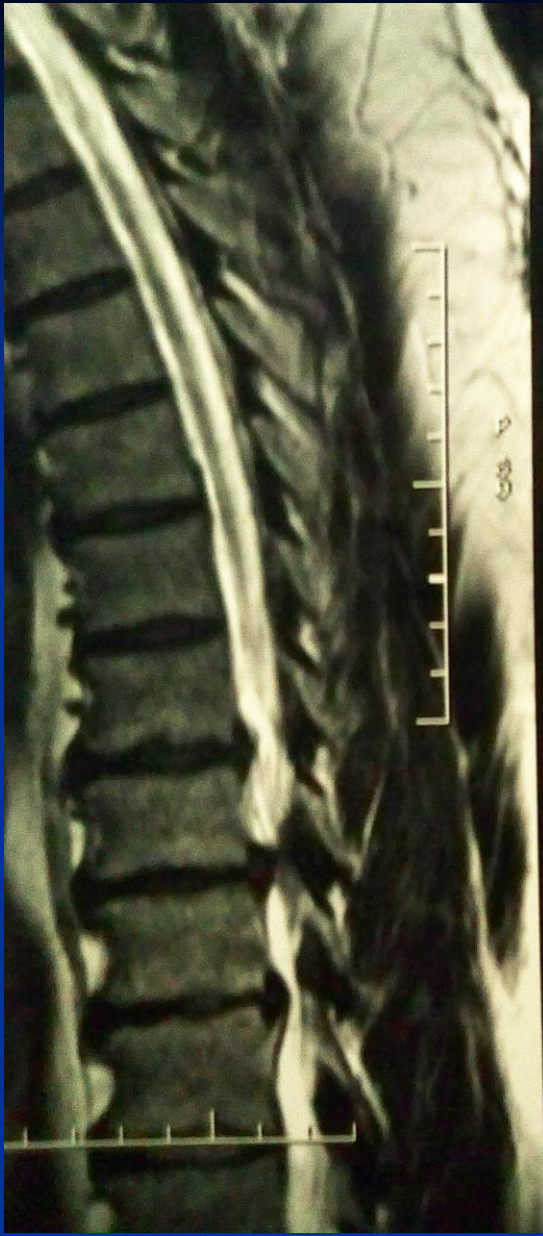Caso 3

- Paciente de 39a. masc.
- Ingresa parapléjico con nivel sensitivo T11

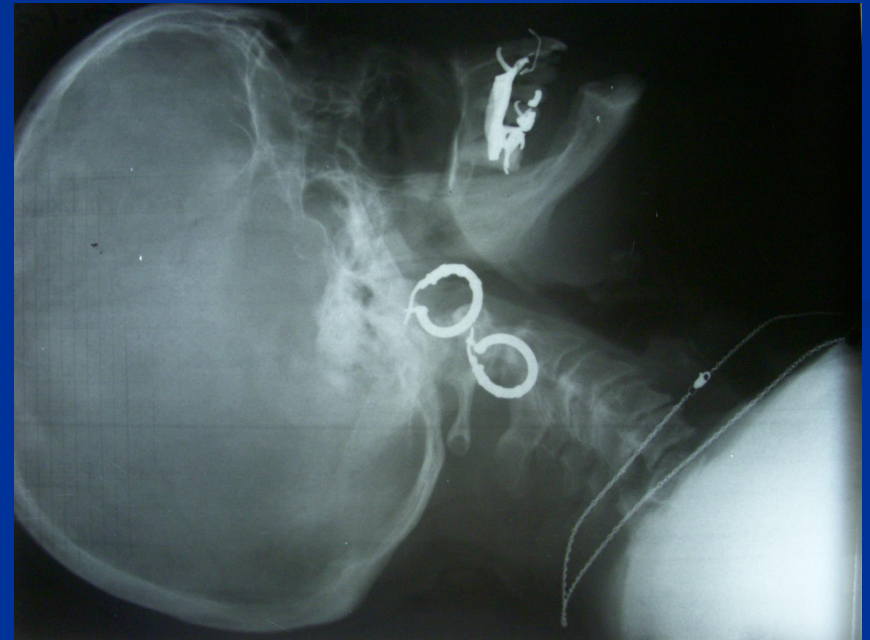

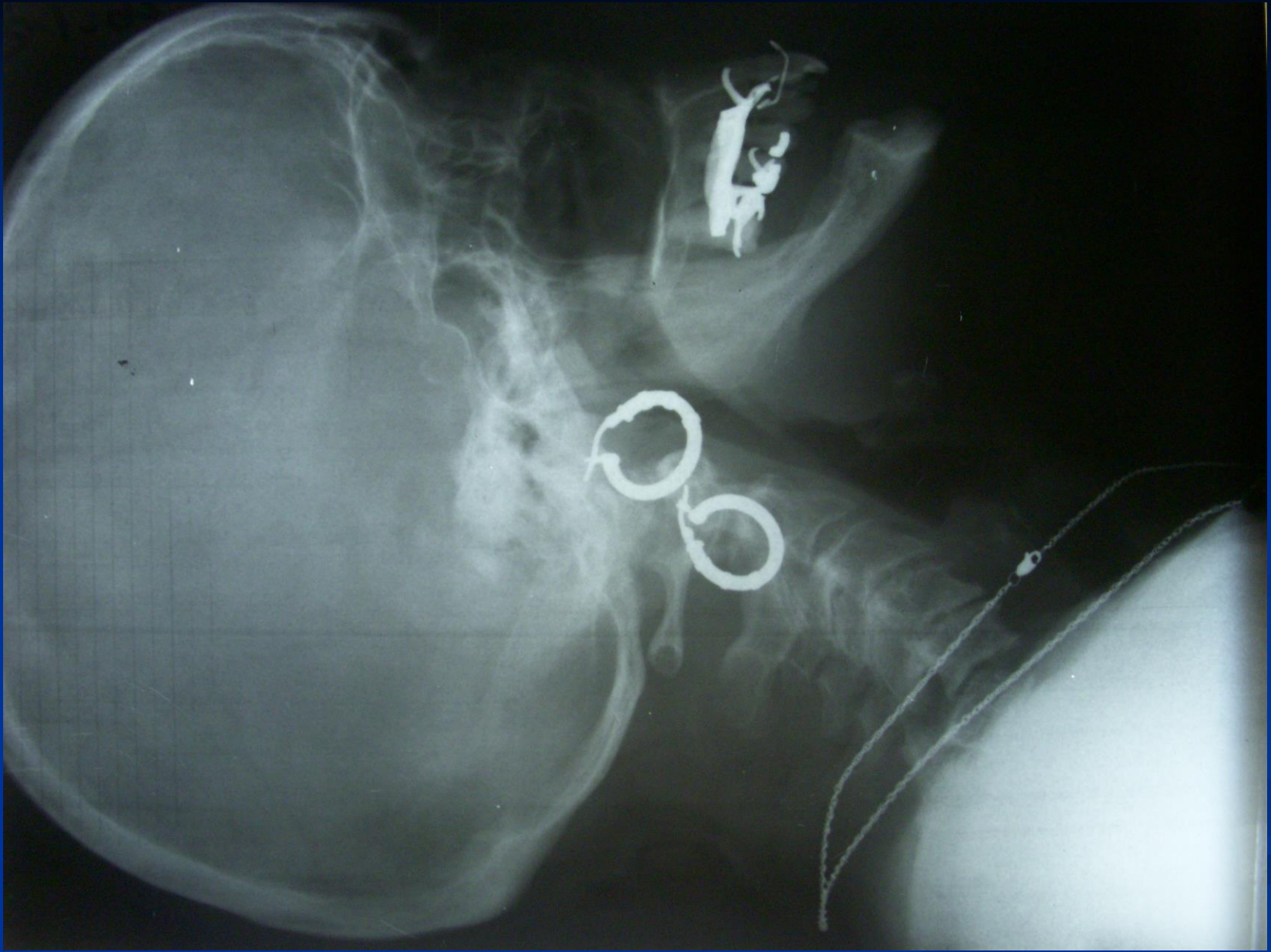




Caso 4

- Paciente de 65a., fem.
- Dolor cervical sin irradiación.
- Sin déficit neurológico.
- Antecedentes: trauma en flexión 7 días antes.





COLUMNA

GYROSCAN T5-II

COLUMNA

FEMIENLALO SUSANA
JAN-08# 690 F
11:3916-JUN-1943

FUNDACION FEMIENLALO SUSANA
27-JAN-08# 690
11:3916-JUN-1943

*T1W.SAG+GAD
SCAN 10
TR 674
TE 14

*T1W.SAG+GA
SCAN 10
TR 67
TE 1

FOV 275
RIGHT 1.9
SLICE 6/ 9

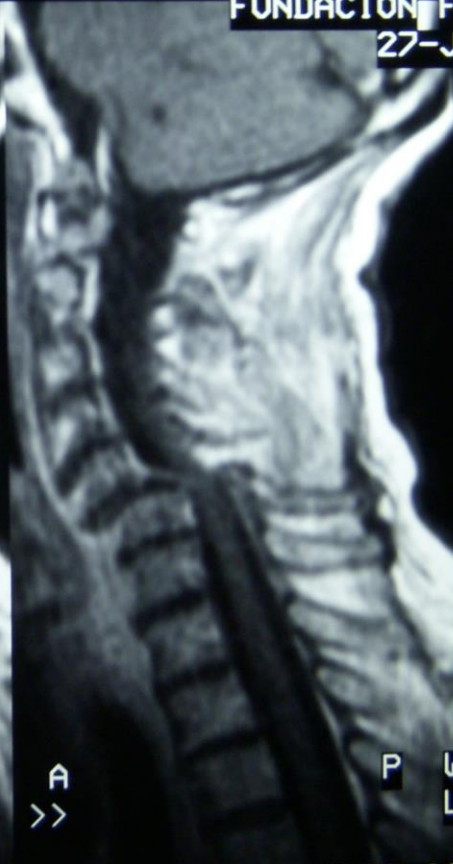
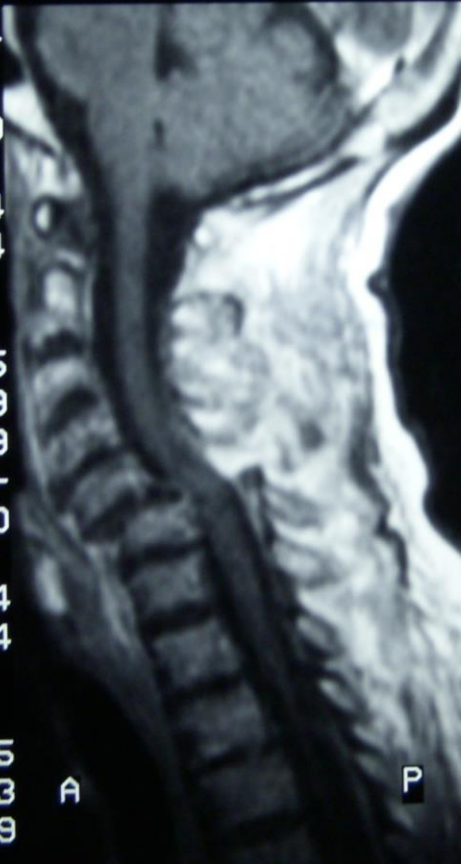
FOV 27
RIGHT 10.
SLICE 8/

*T1W.SAG+GAD
SCAN 10
TR 674
TE 14

*T1W.SAG+GA
SCAN 10
TR 67
TE 1

FOV 275
W 1657 RIGHT 6.3 A
L 781 SLICE 7/ 9

FOV 27
W 1657 RIGHT 15.
L 781 SLICE 9/



P A
>>

GYROSCAN T5-II

COLUMNA

COLUMNA

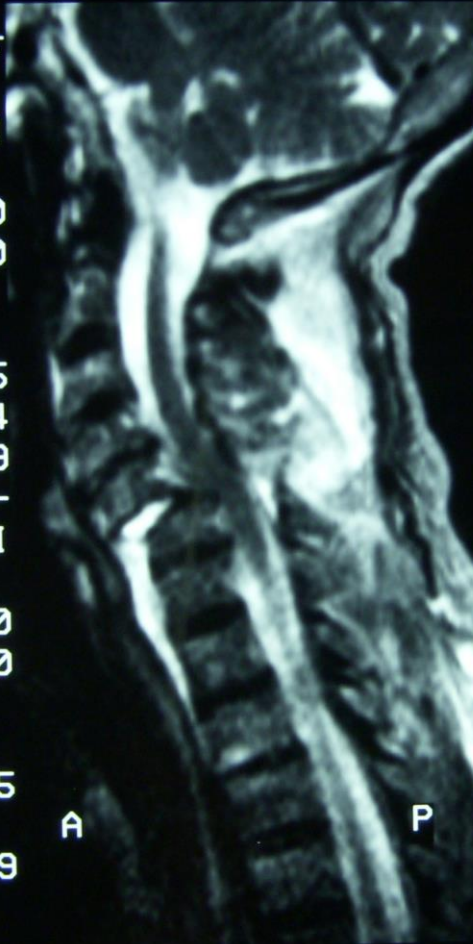
LALO SUSANA
690 F
16-JUN-1943
*T2W/TSE MI
SCAN 3
TR 5000
TE 150

FOV 245
LEFT -4.4
SLICE 4/ 9

*T2W/TSE MI
SCAN 3
TR 5000
TE 150

FOV 245
SLICE 5/ 9

COLUMNA



FUNDACION FEMIENLALO SUSANA
27-JAN-08 # 690

10:58 16-JUN-1943

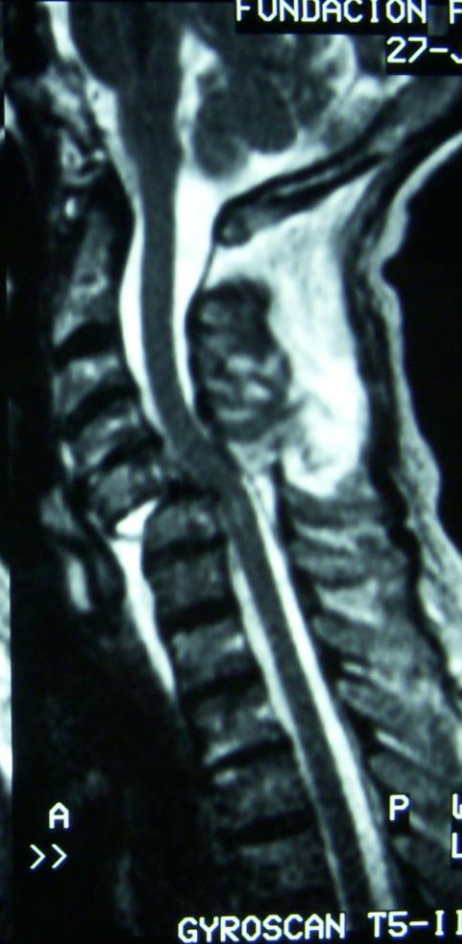*STIR/TSE I
SCAN 6
TR 1600
TE 150

FOV 245
LEFT -6.4
SLICE 4/ 9

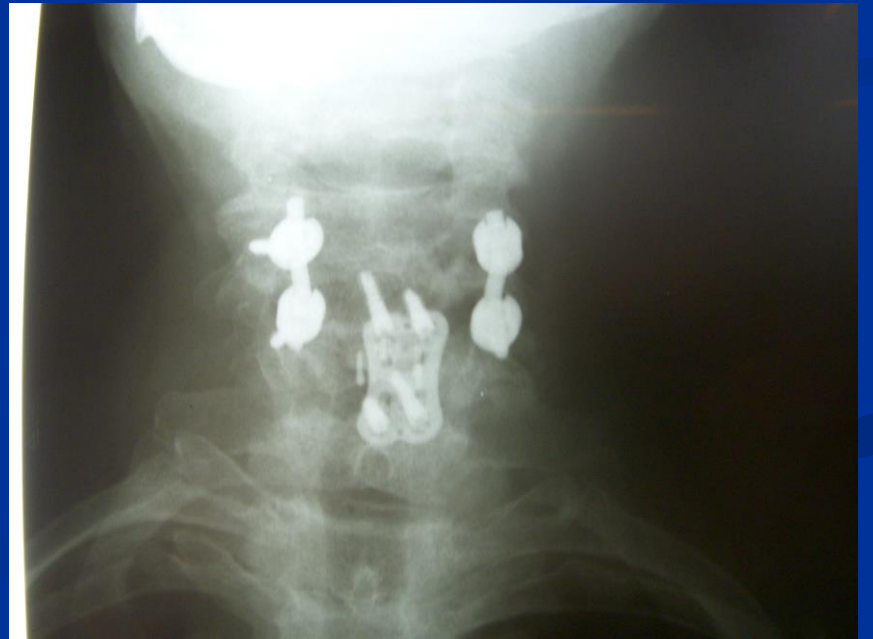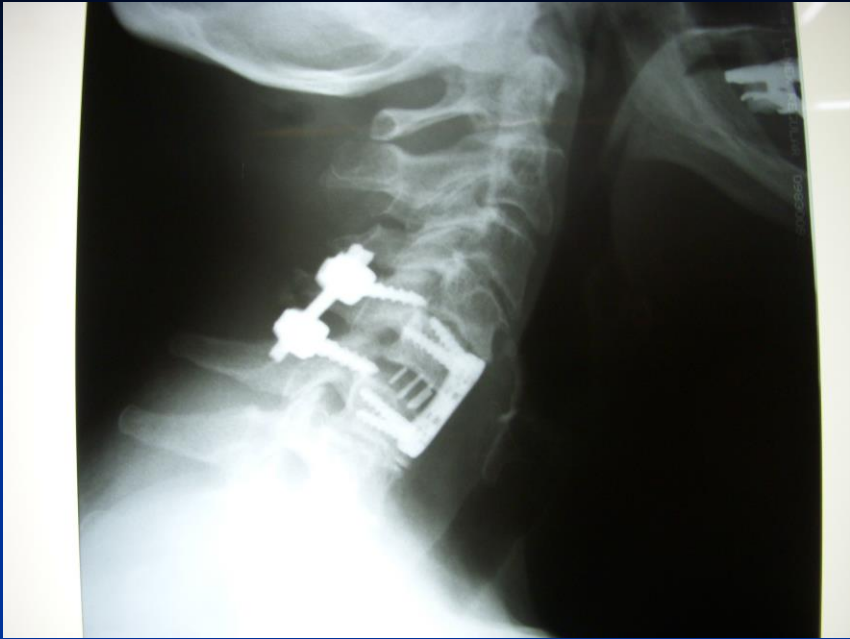*STIR/TSE I
SCAN 6
TR 1600
TE 150

FOV 245
P W 1819 LEFT -1.4
L 1020 SLICE 5/ 9

COLUMNA

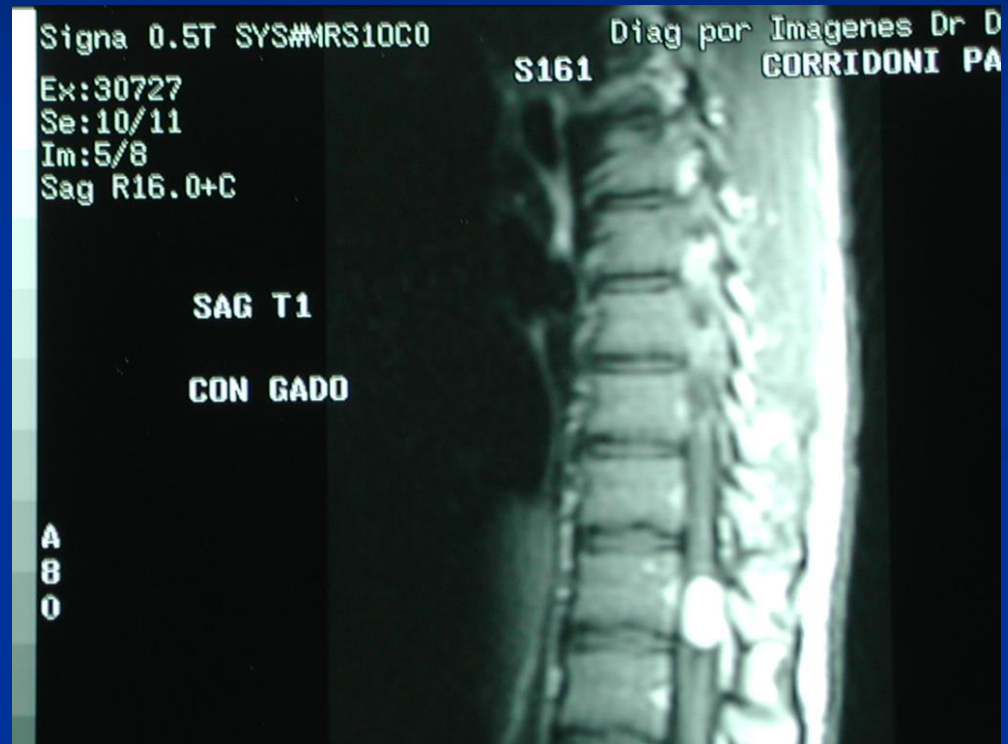

GYROSCAN T5-II



Caso 5

- Paciente 28a., masc
- Dolor irradiado al testículo derecho.
- Sin déficit neurológico.



Signa 0.5T SYS#MRS10C0

Diag por Imagenes Dr Deragopyan

Ex:30727

SP

CORRIDONI PABLO[C D]

Se:9/11

28 M 727

Im:5/8

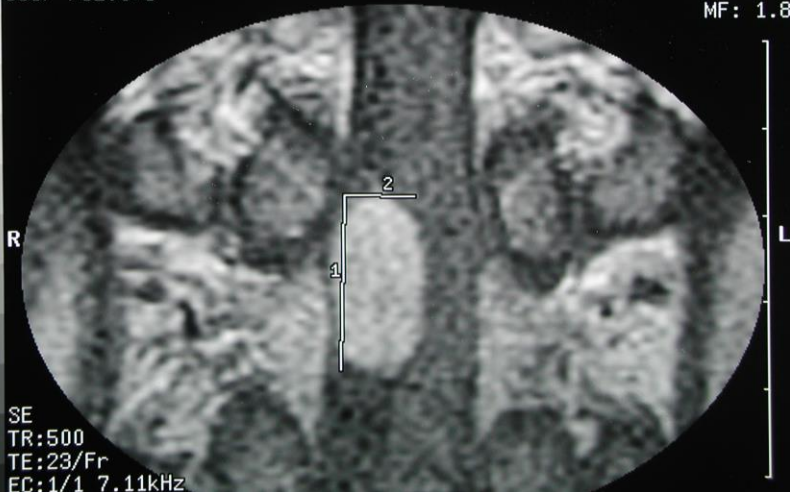
CORONAL T 1 CON GADO

16/11/01

OCor P32.0+C

21:37

MF: 1.8



SE
TR:500
TE:23/Fr
EC:1/1 7.11kHz

Signa 0.5T SYS#MRS10C0

Diag por Imagenes Dr Deragopyan

Ex:30727

AS

CORRIDONI PABLO[C D]

Se:8/11

28 M 727

Im:17/24

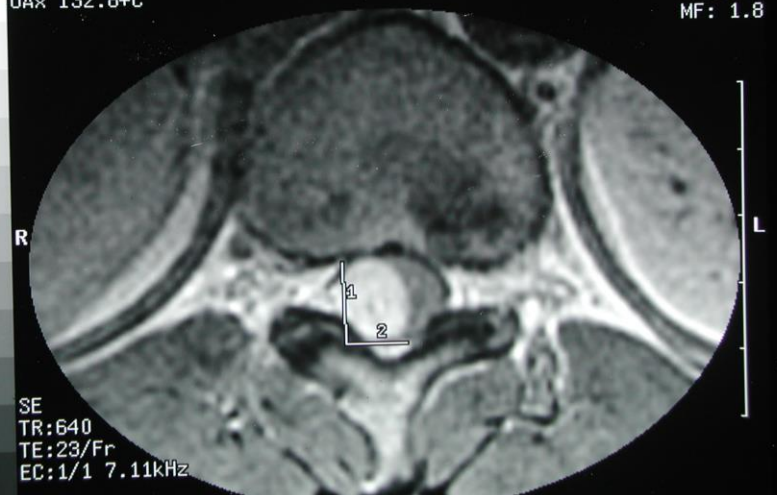
AXIAL T 1 CON GADO

16/11/01

OAx I32.8+C

21:30

MF: 1.8



SE
TR:640
TE:23/Fr
EC:1/1 7.11kHz

