

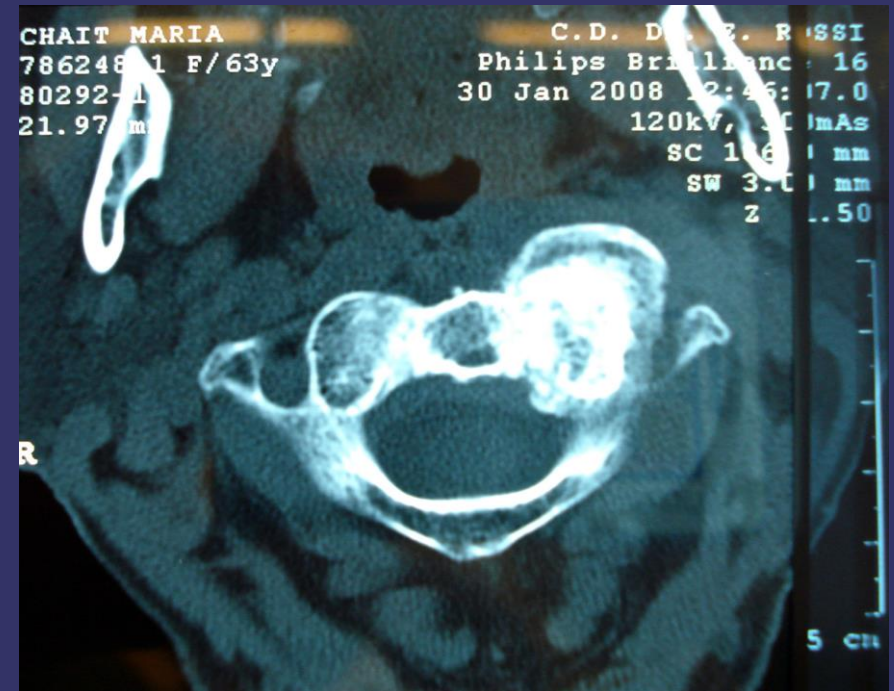
***Ateneo Clínico de Patología de la
Columna Vertebral
14 de Agosto de 2008
Auditorio TRYM***

Dr. Gabriel Jungberg
División Neurocirugía
Hospital General Ignacio Pirovano
Facultad de Medicina
Universidad de Buenos Aires



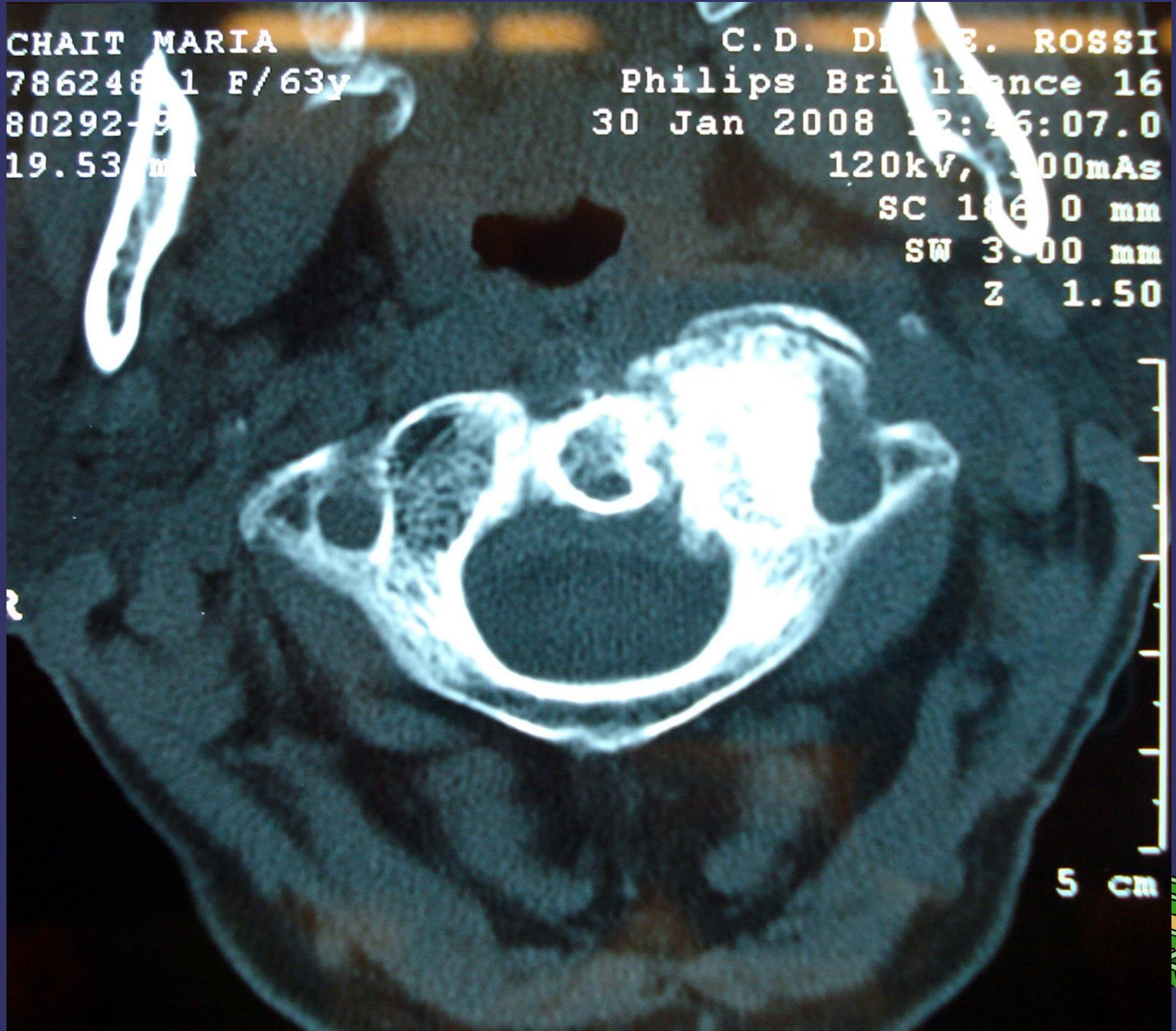
Caso 1

- F 63a.
- Historia de 4a. de dolor láterocervical izquierdo alto que limita la rotación cefálica.
- Neurológicamente intacta.



CHAIT MARIA
7862481 F/63y
80292-9
19.53 mm

C.D. DI E. ROSSI
Philips Brilliance 16
30 Jan 2008 12:46:07.0
120kV, 300mAs
SC 186.0 mm
SW 3.00 mm
Z 1.50

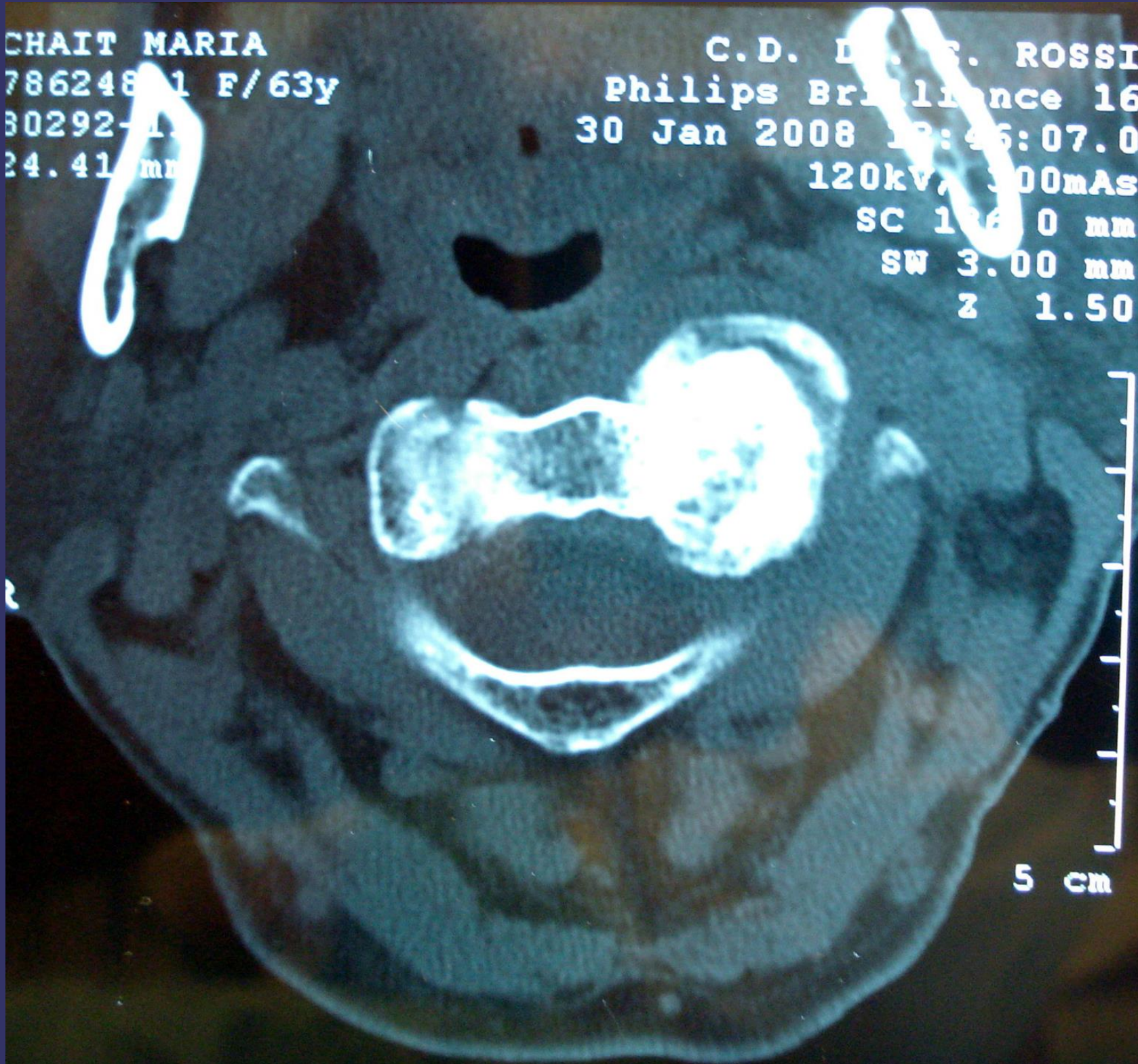

5 cm



CHAIT MARIA
786248-1 F/63y
30292-1
24.41 mm

C.D. D. S. ROSSI
Philips Brilliance 16
30 Jan 2008 12:46:07.0
120kV, 300mAs
SC 136.0 mm
SW 3.00 mm
Z 1.50



CHAIT MARIA
78624801 F/63y
80292-12
26.85 mm

C.D. R. E. ROSSI
Philips Brilliance 16
30 Jan 2008 18:46:07.0
120kV, 300mAs
SC 184.0 mm
SW 3.00 mm
Z 1.50

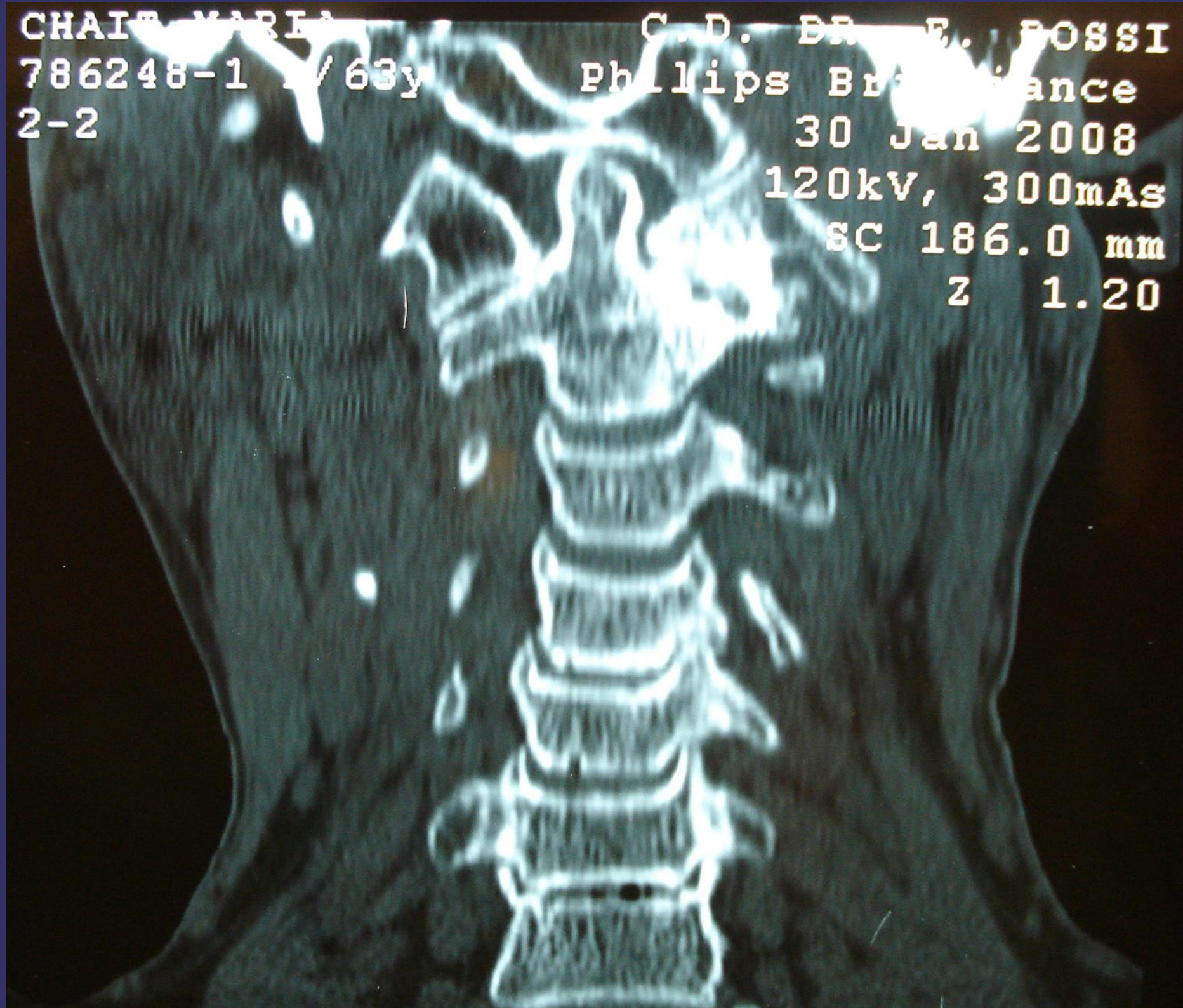R

5 cm



CHAIR MARI
786248-1 / 63y
2-2

C.D. DR. E. BOSSI
Philips Brilliance
30 Jan 2008
120kV, 300mAs
SC 186.0 mm
Z 1.20



CHAIR MARIA

C.D. DR. ROSSI

786248-1 EV 63y

Philips Brilliance

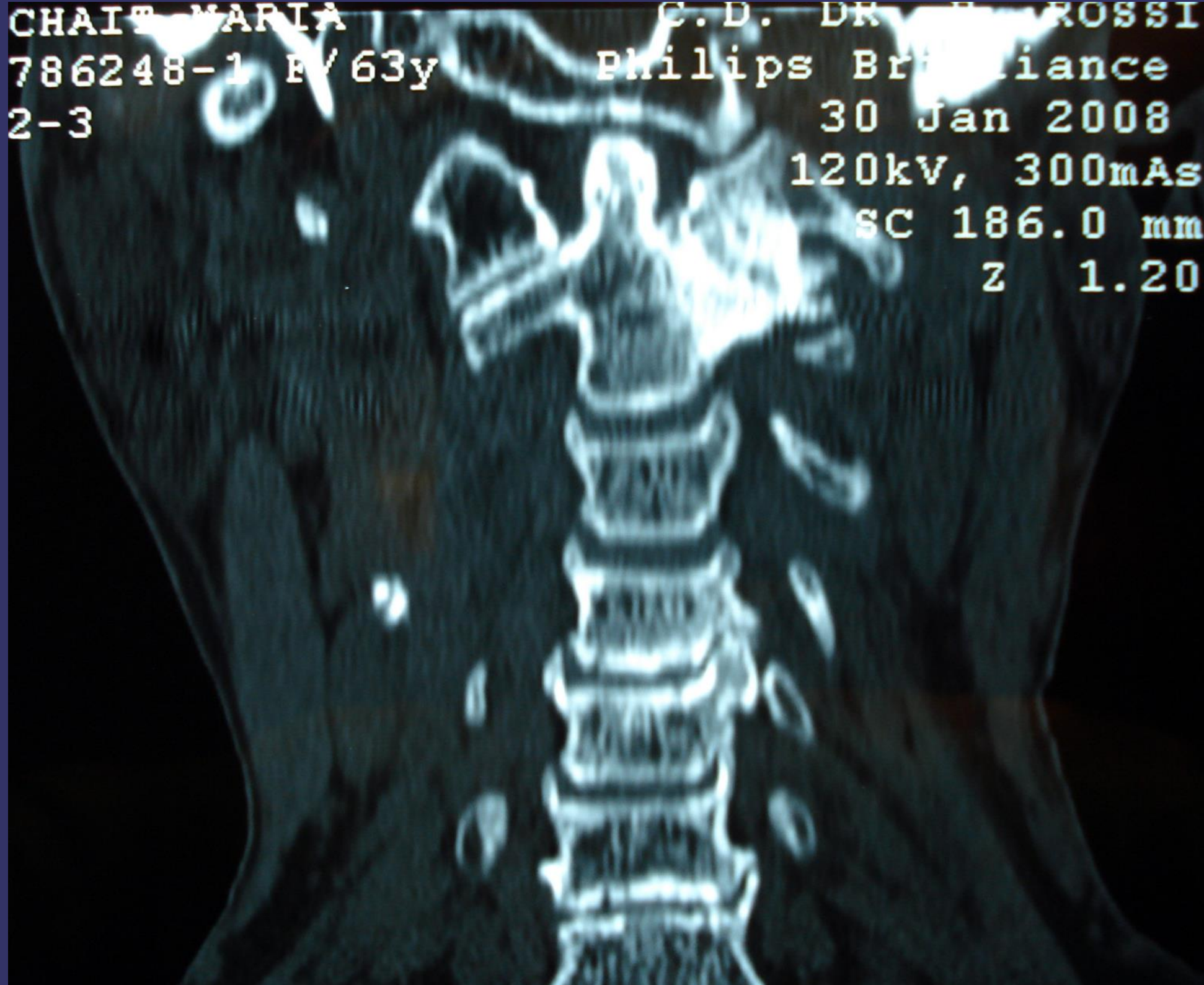2-3

30 Jan 2008

120kV, 300mAs

SC 186.0 mm

Z 1.20



MARIA ESTER CHAIT
352828
24 Jan 2008, 22:11


PHL

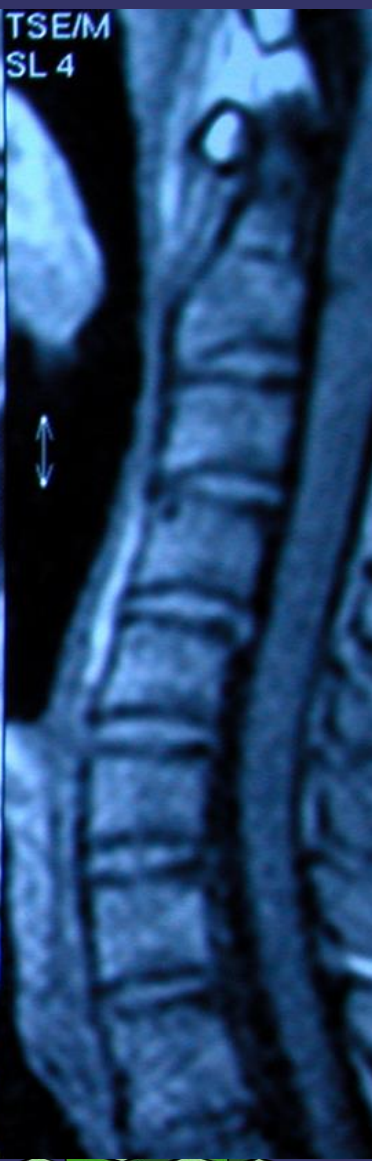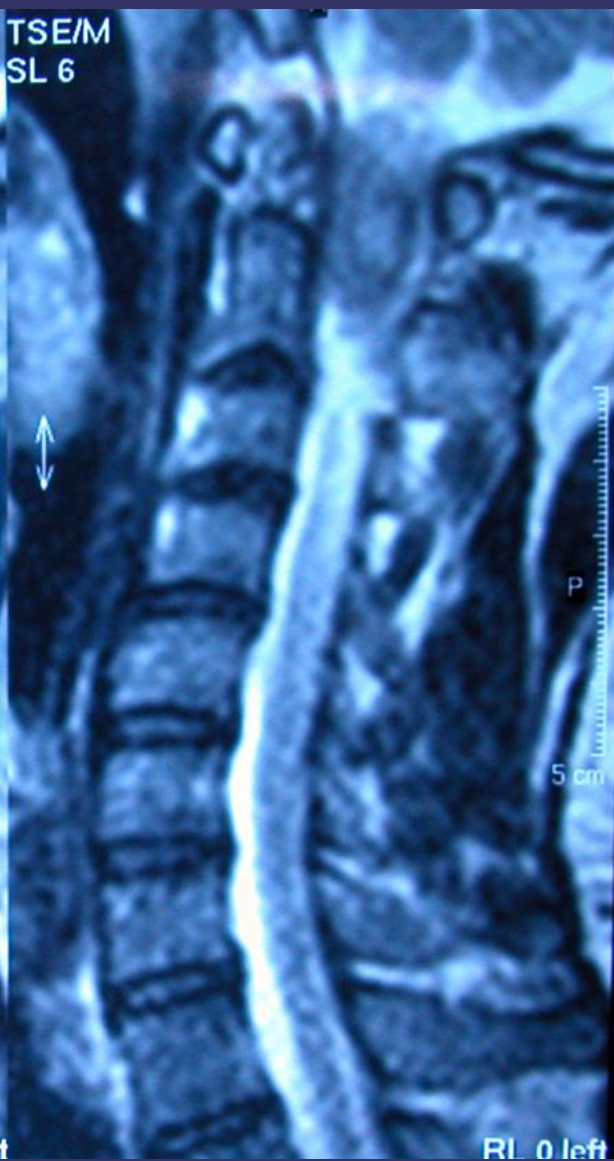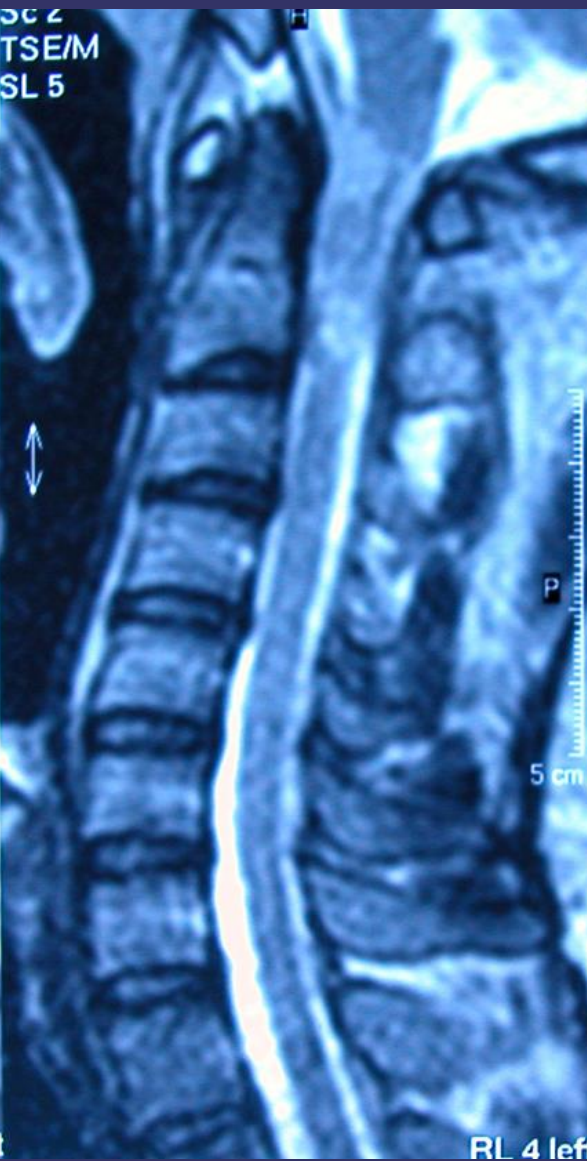
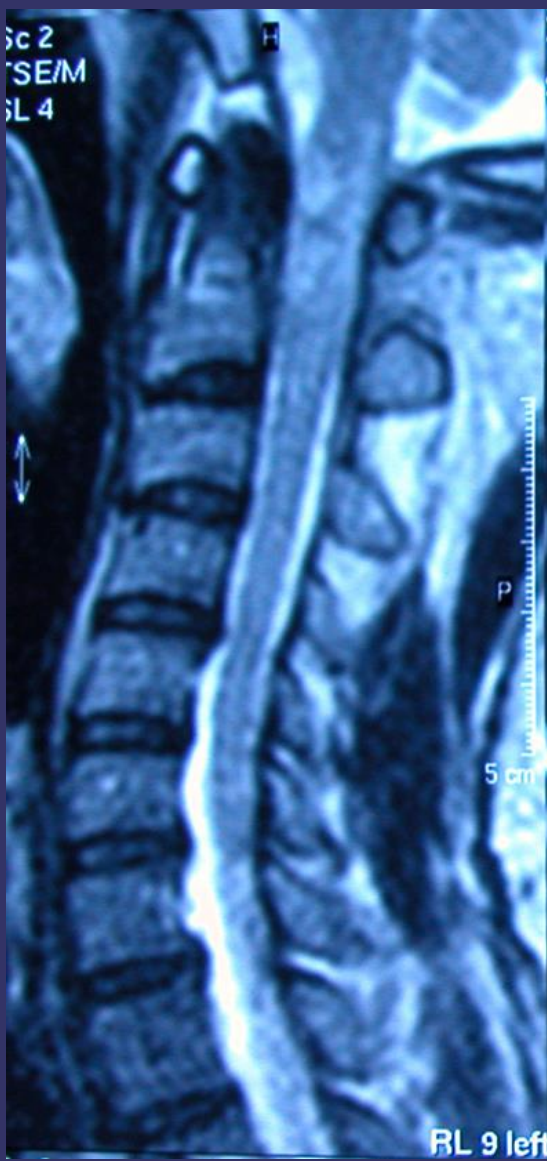C.D.D.T. L. ROSSA

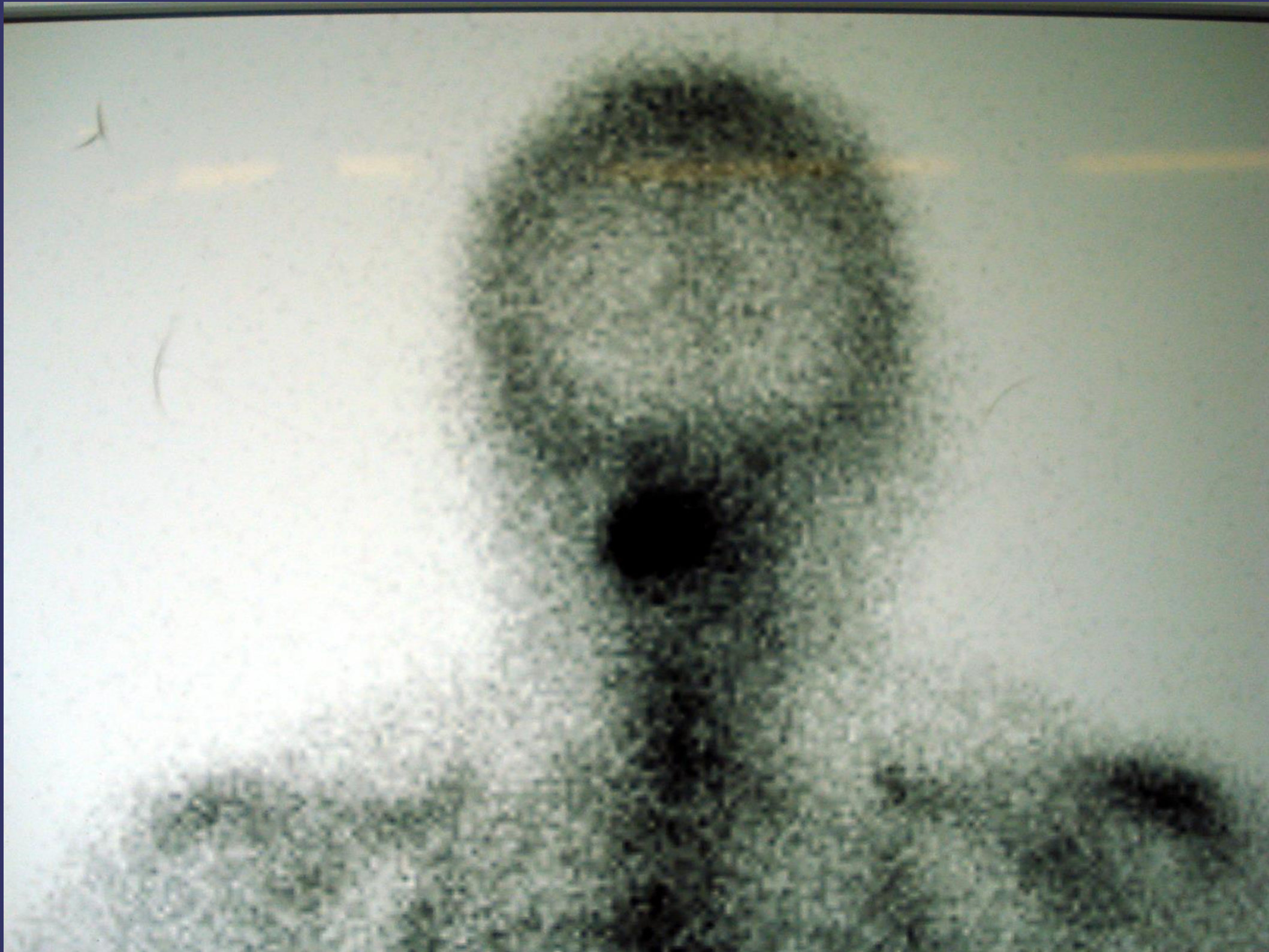
COL.CERVICAL

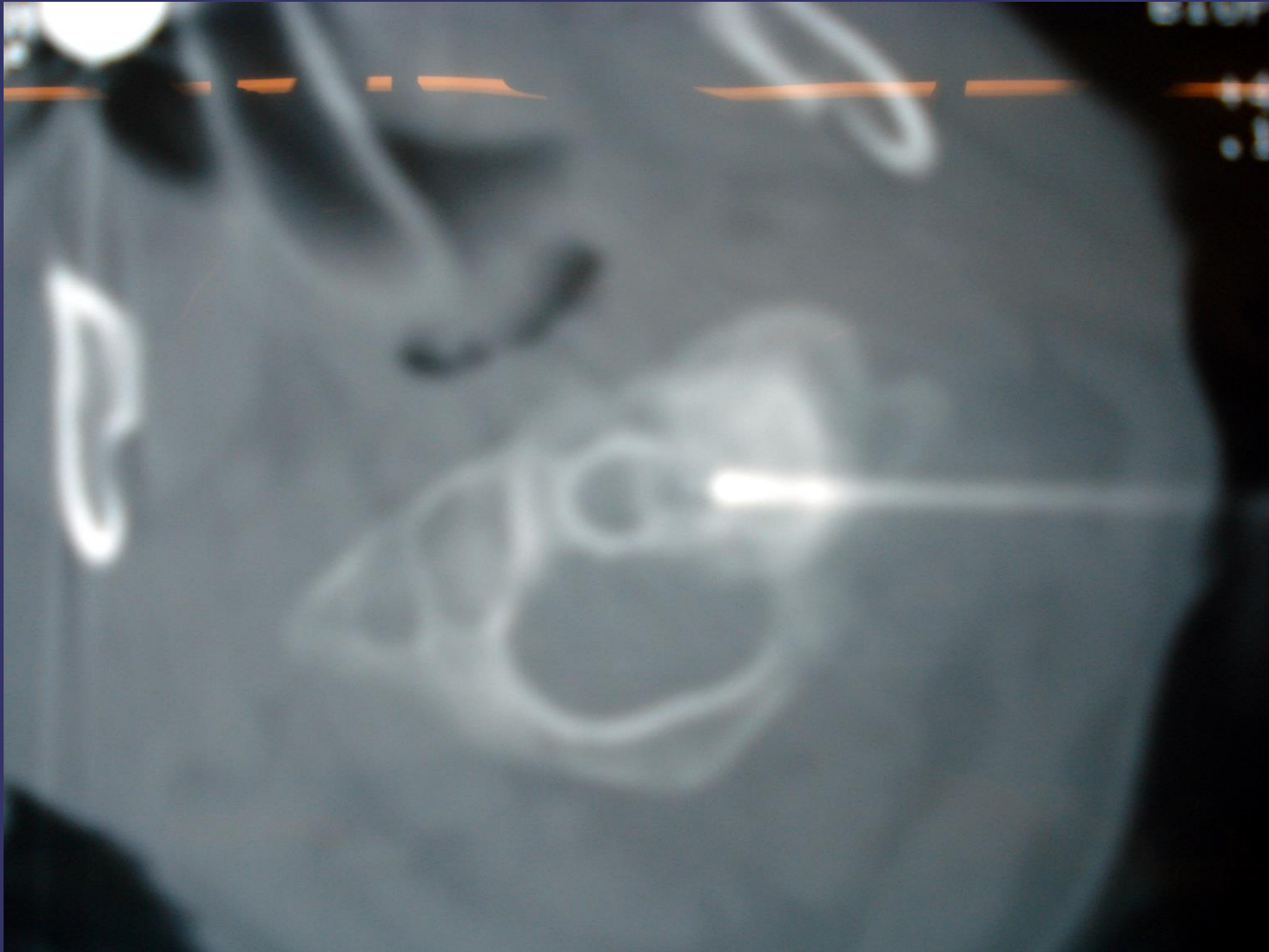
NoC

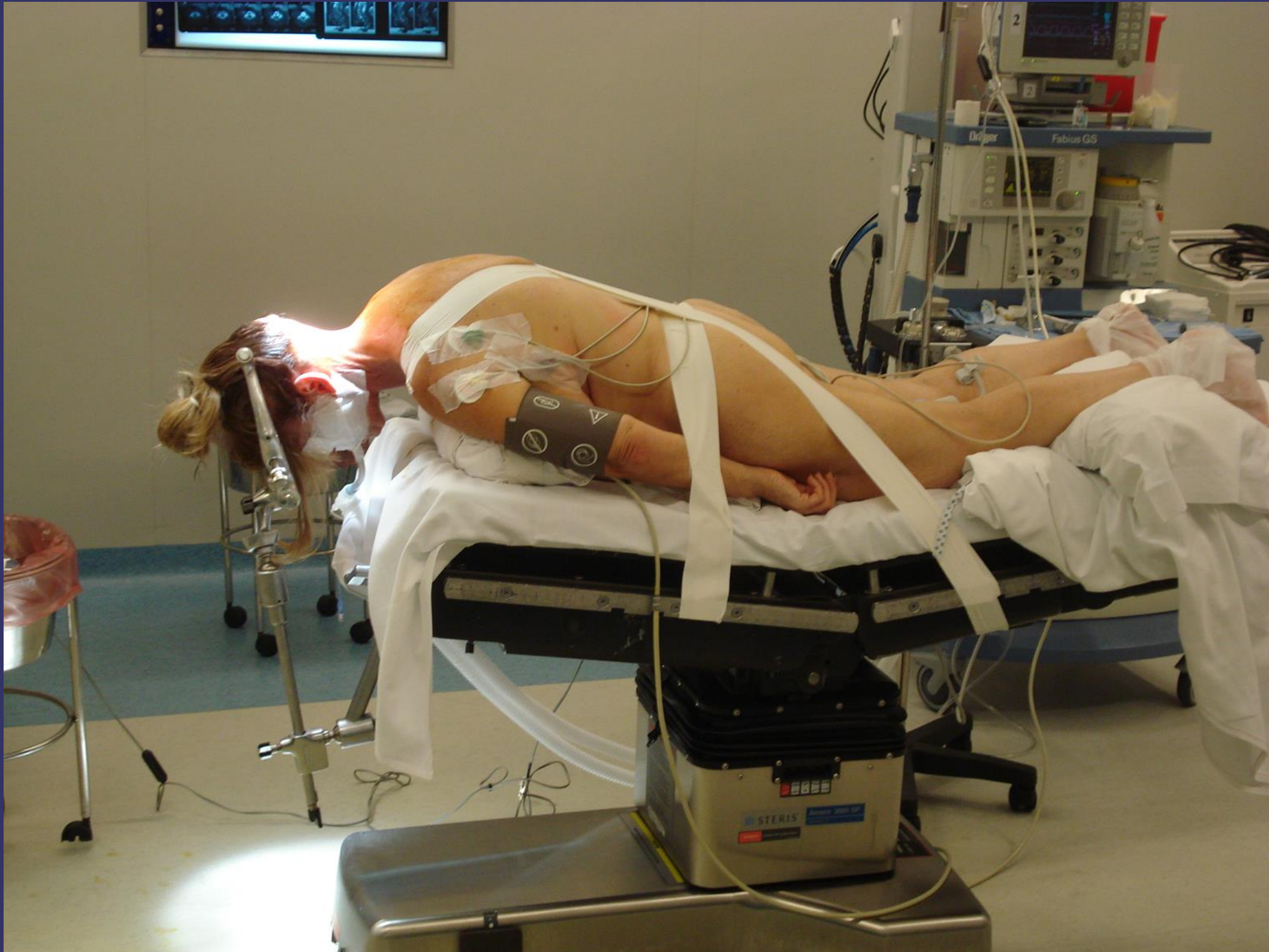
PER

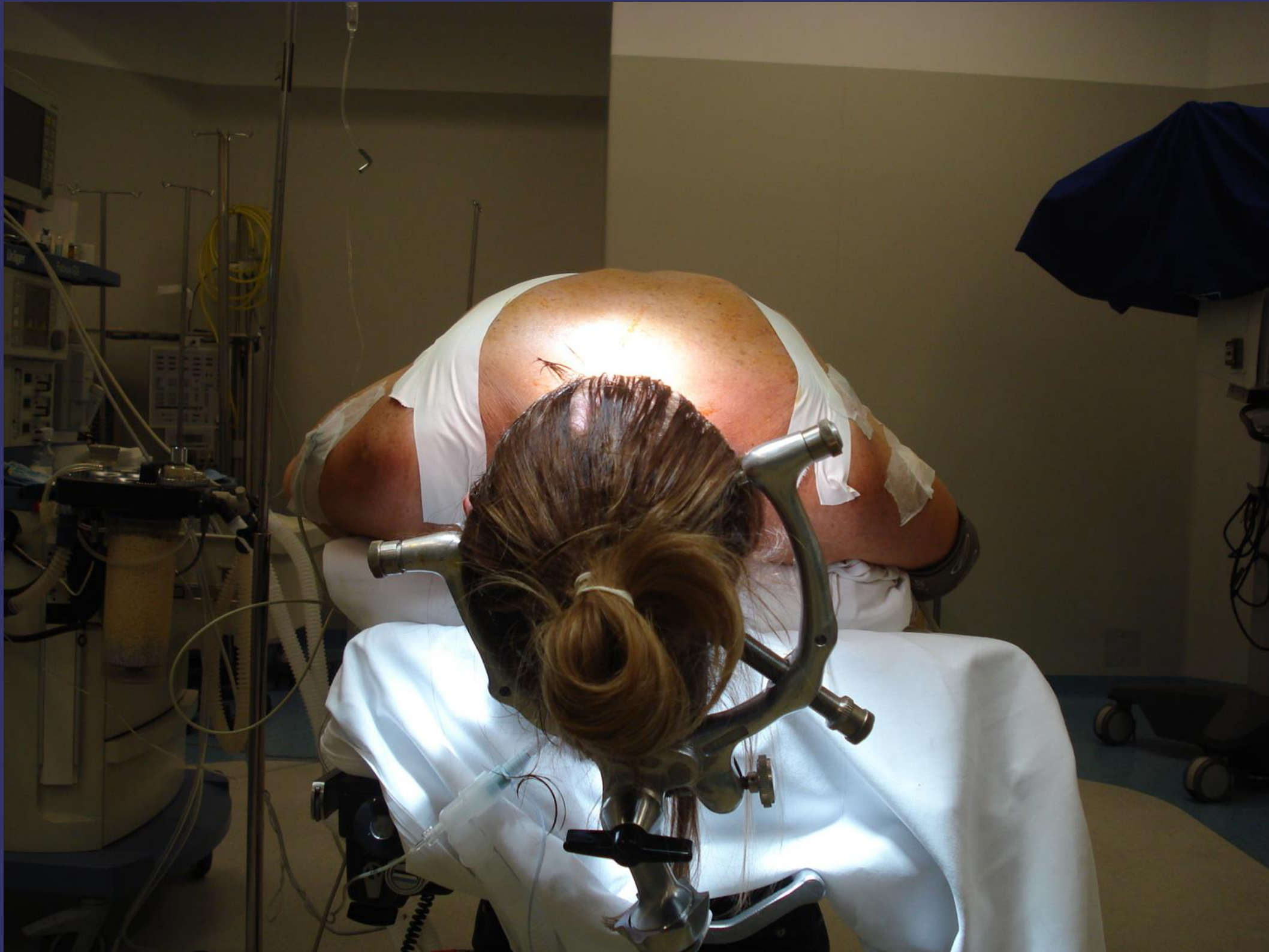


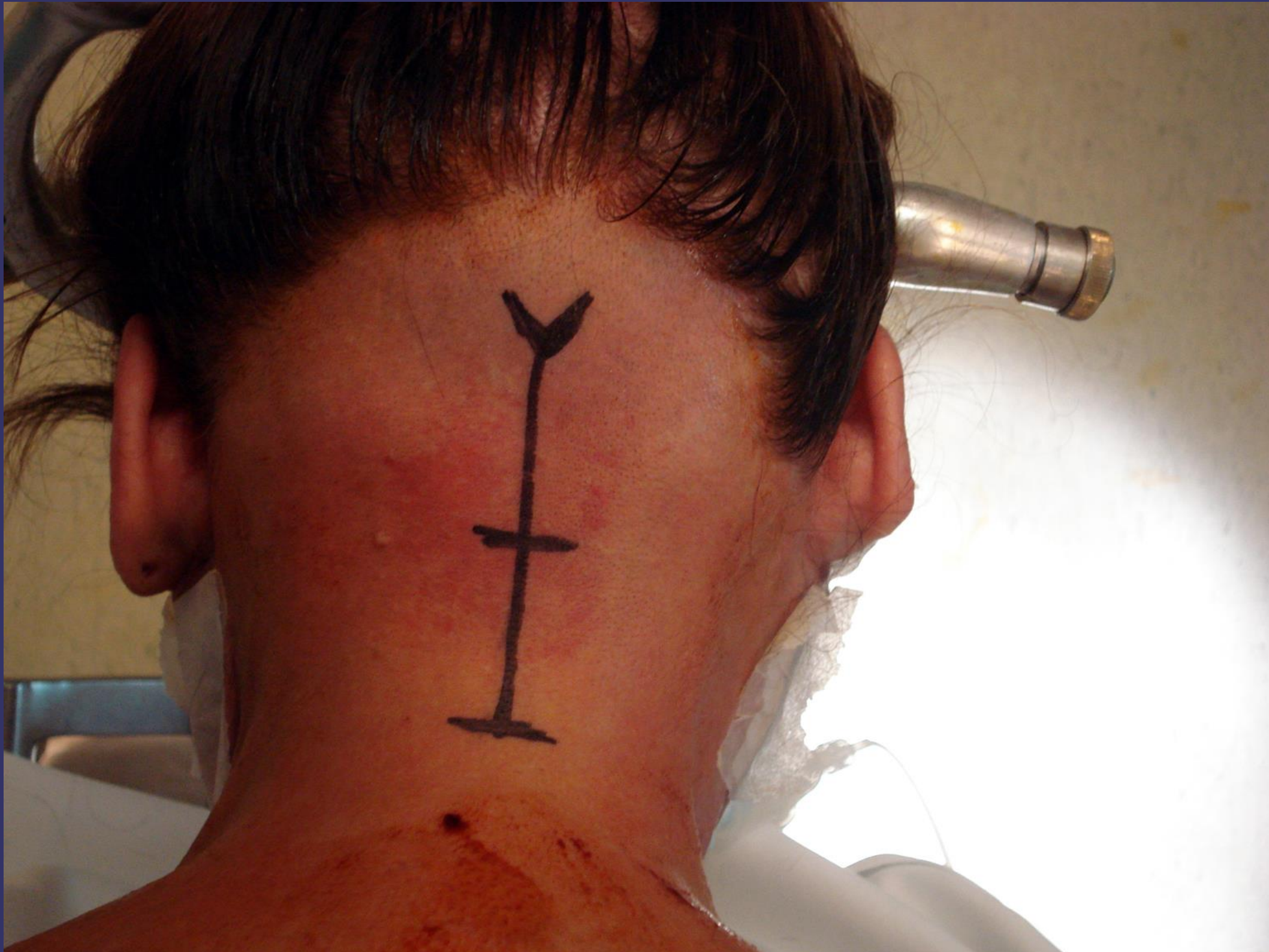
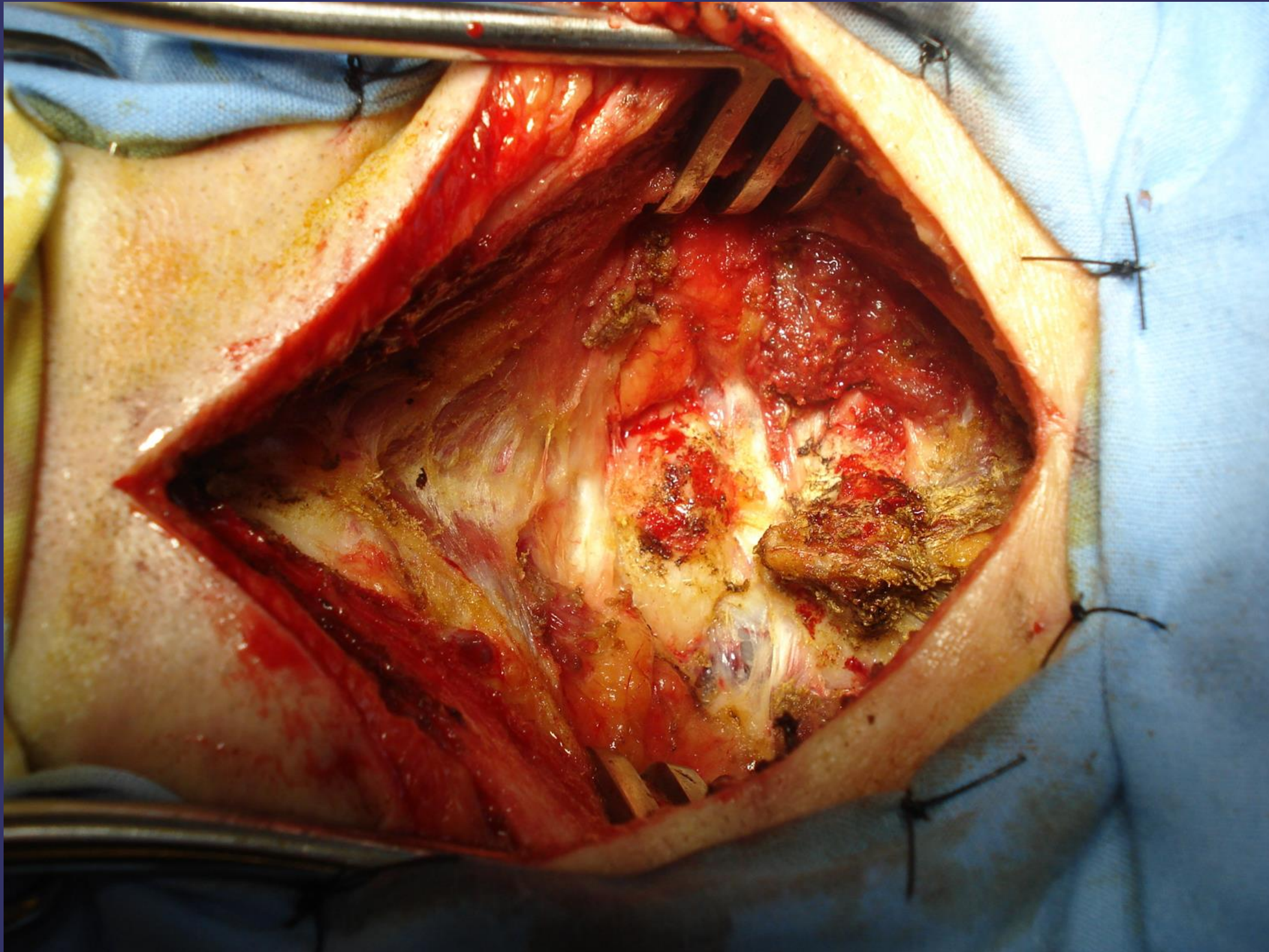


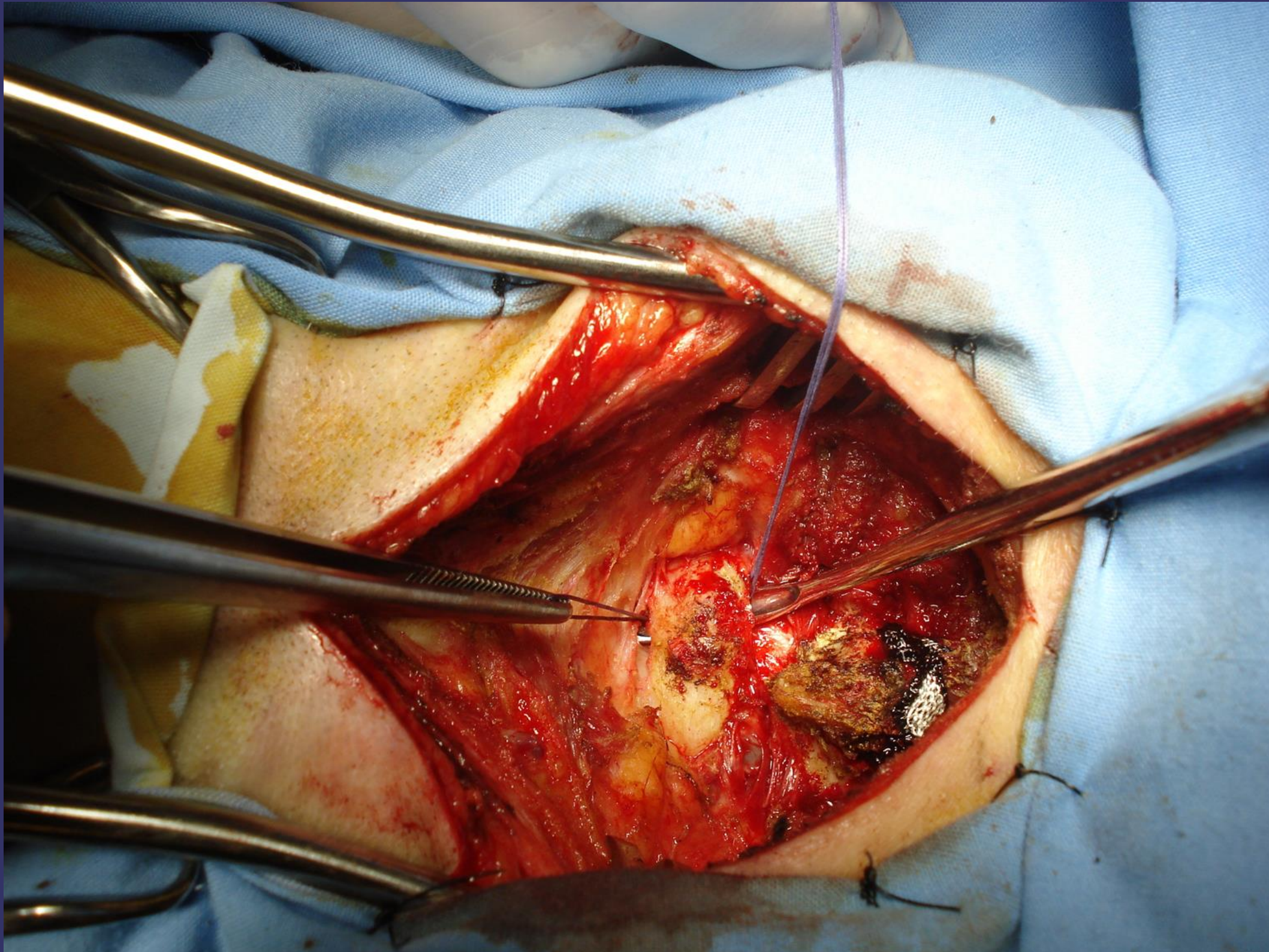


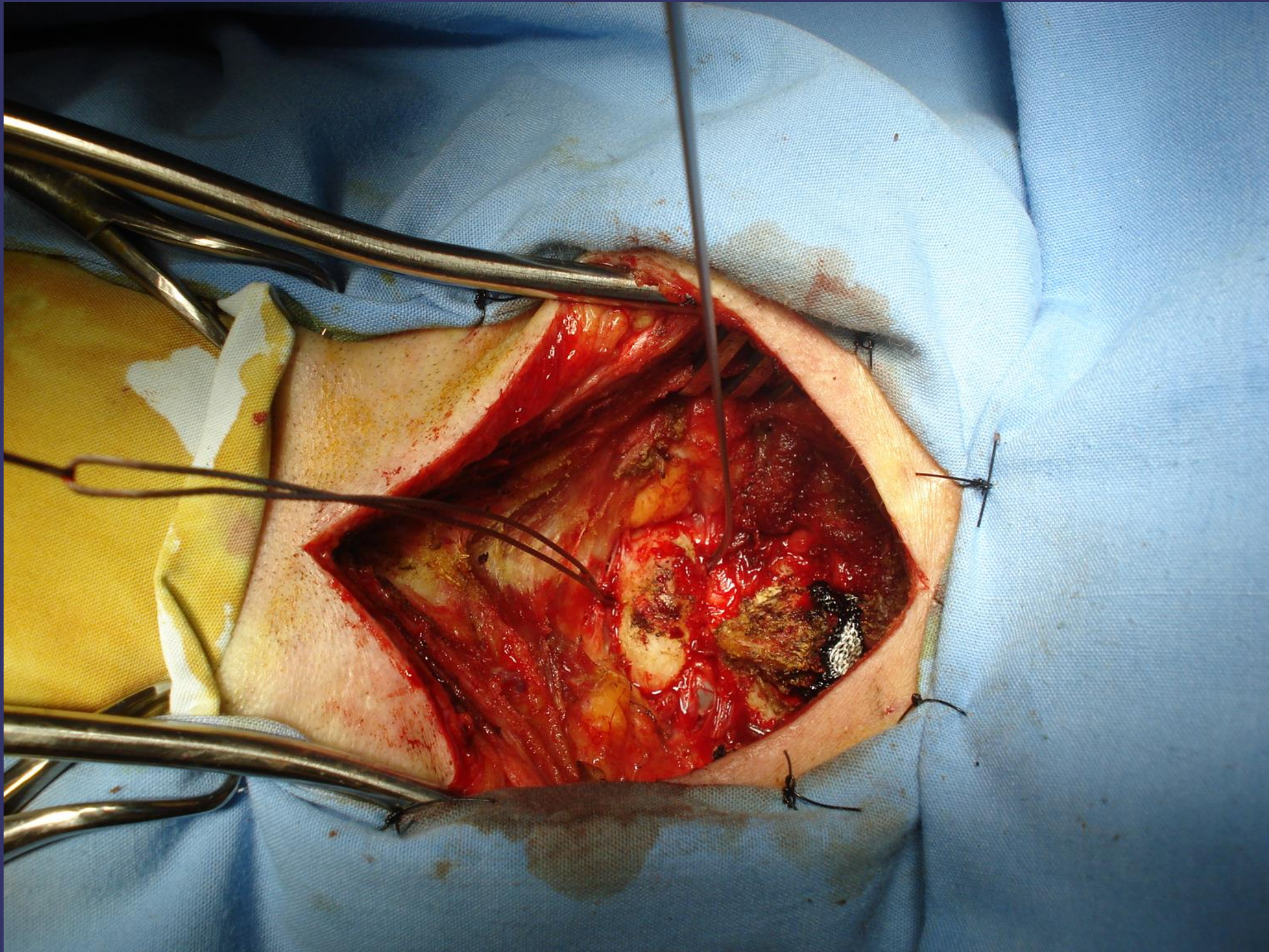


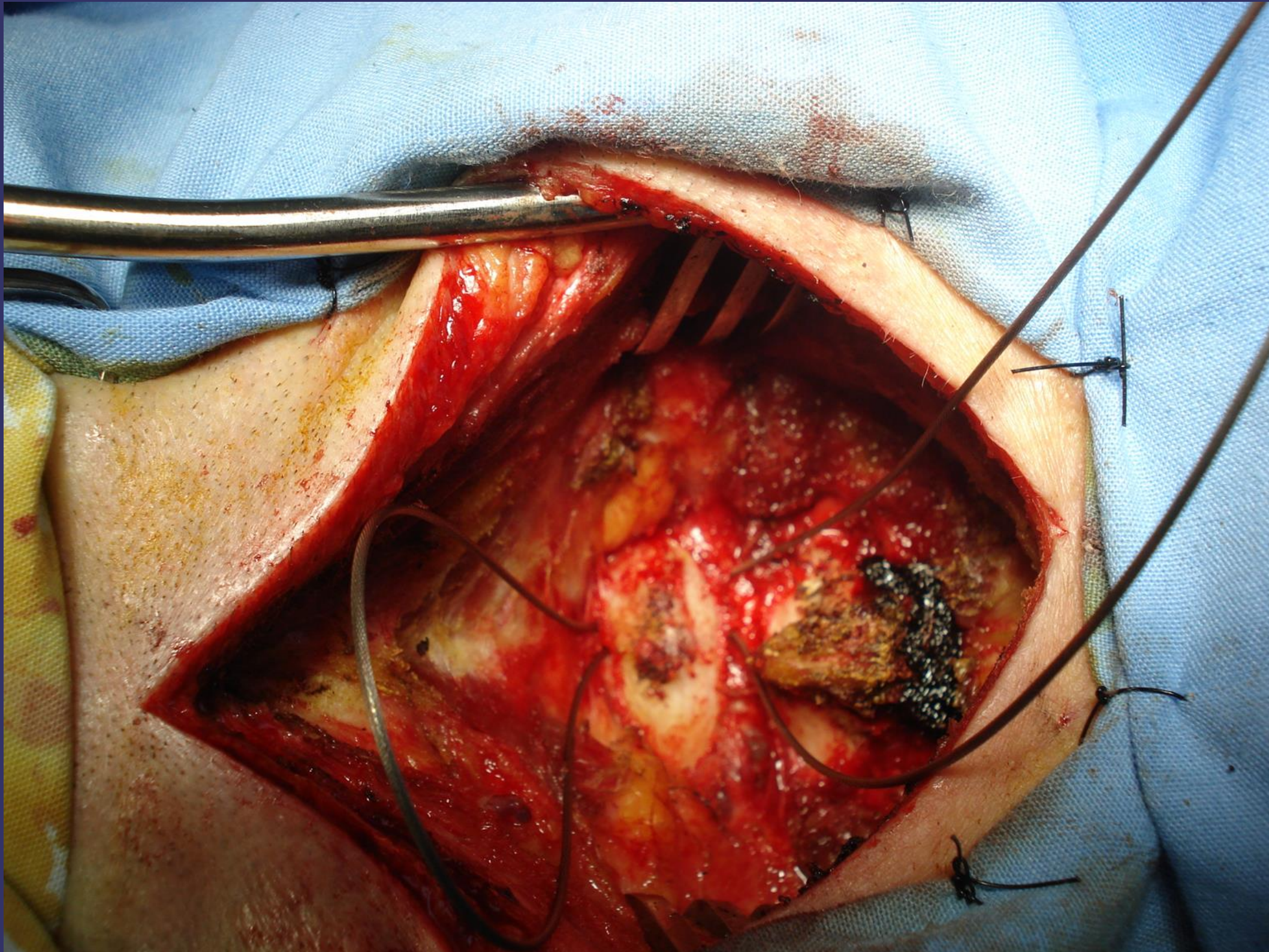


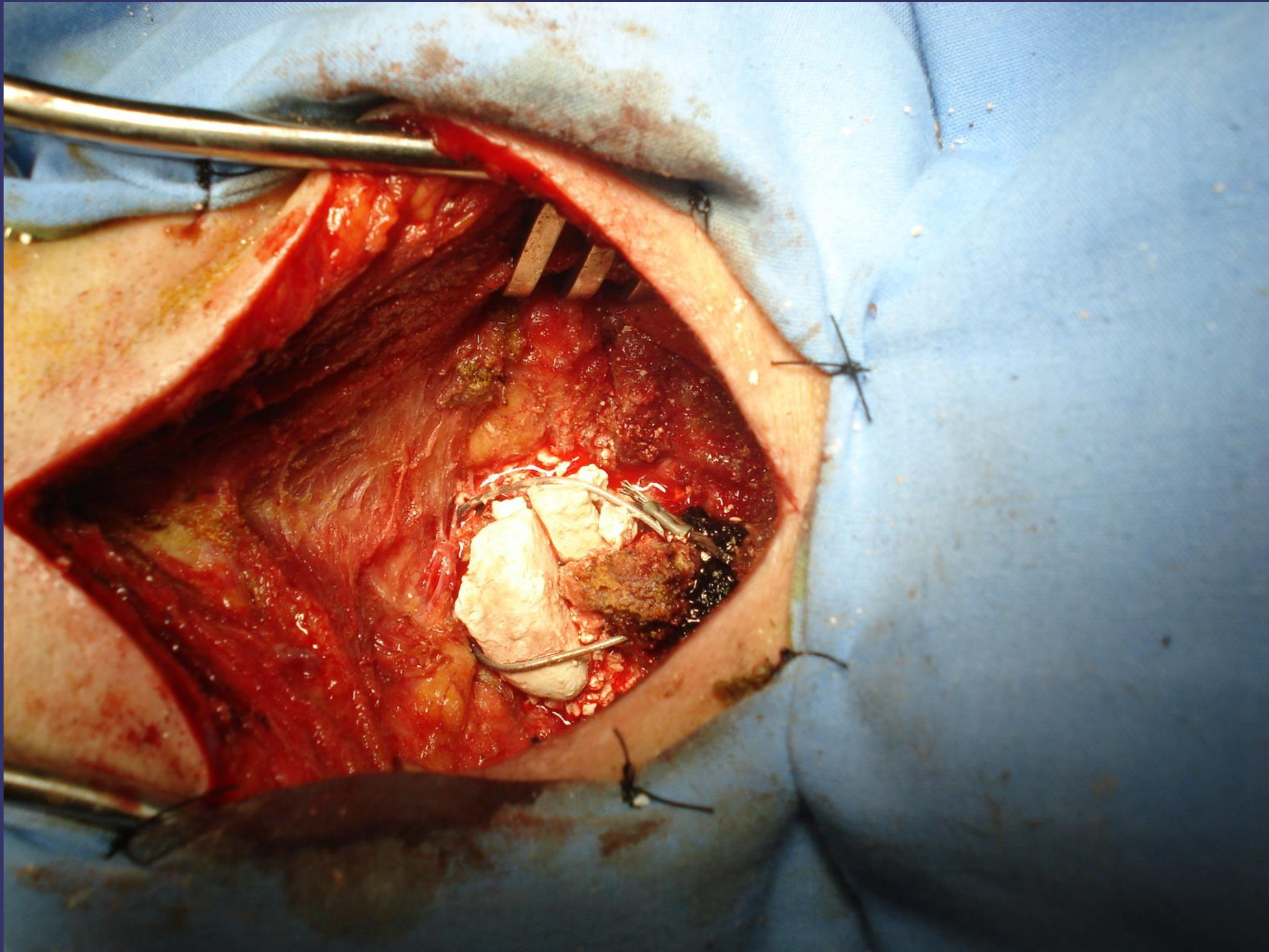


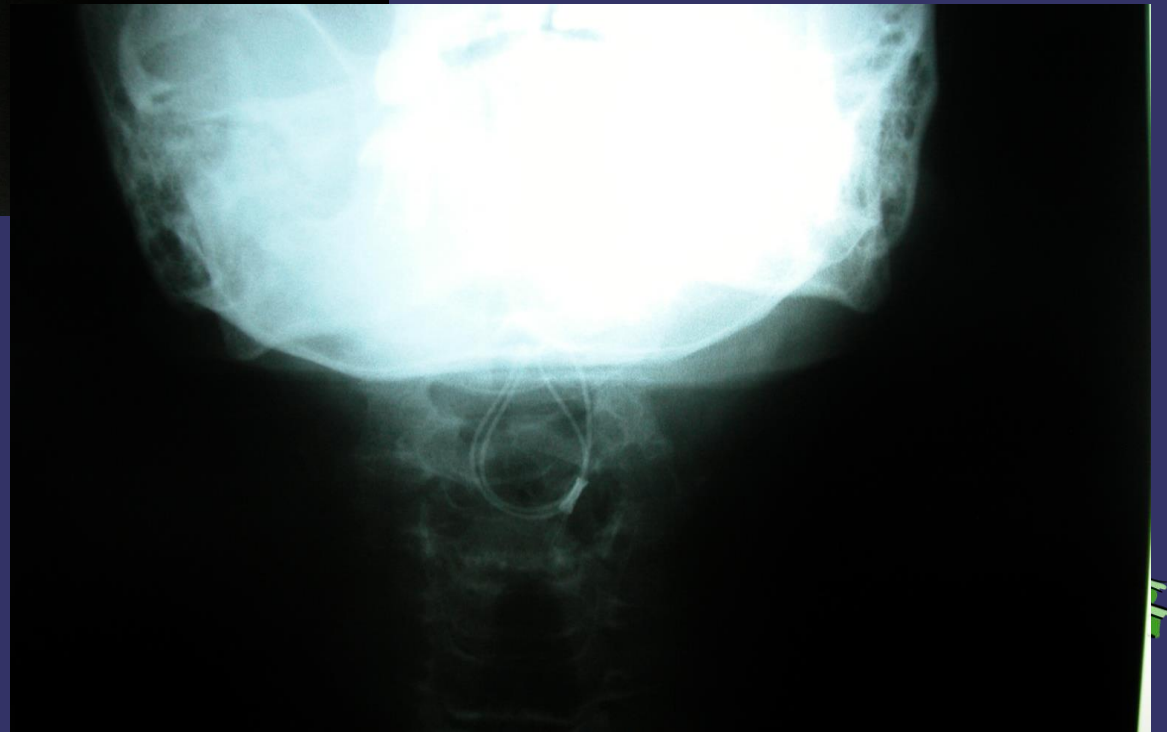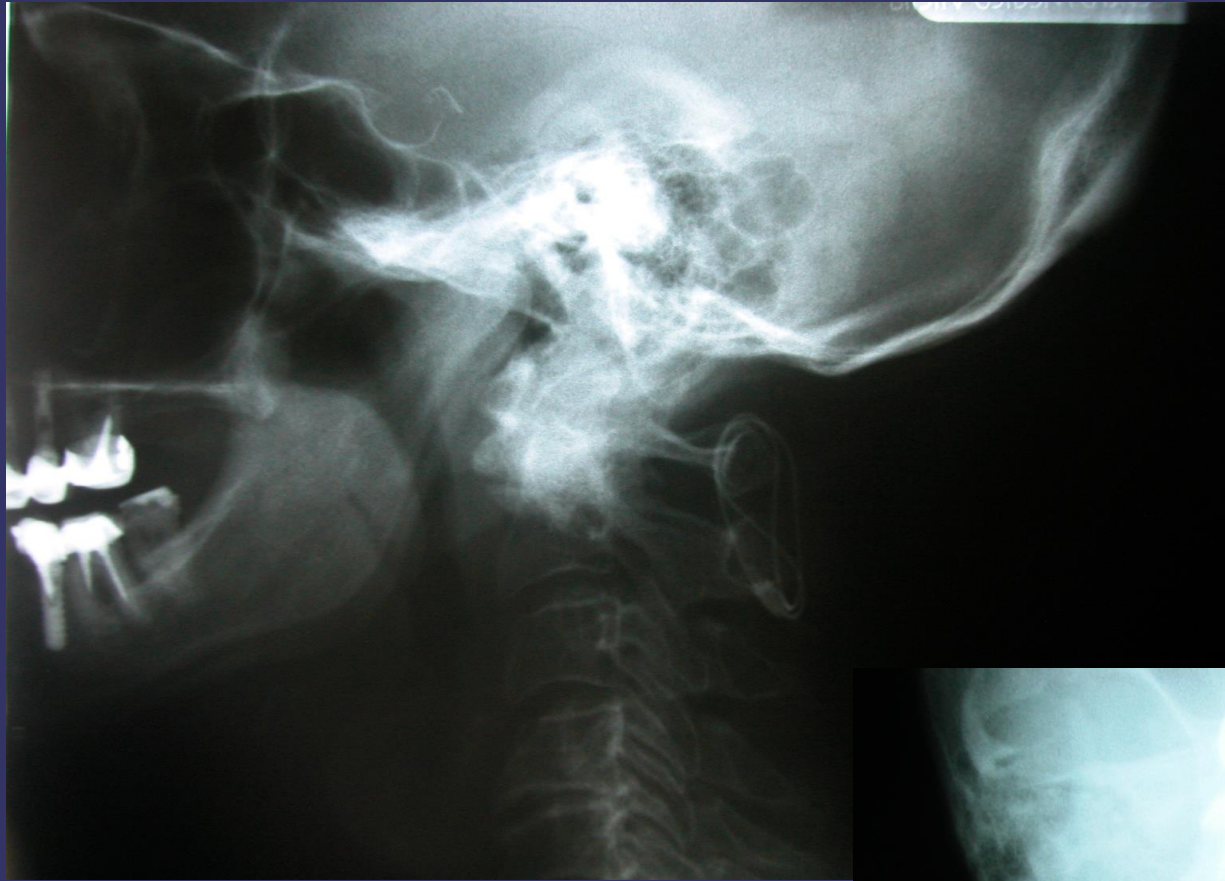


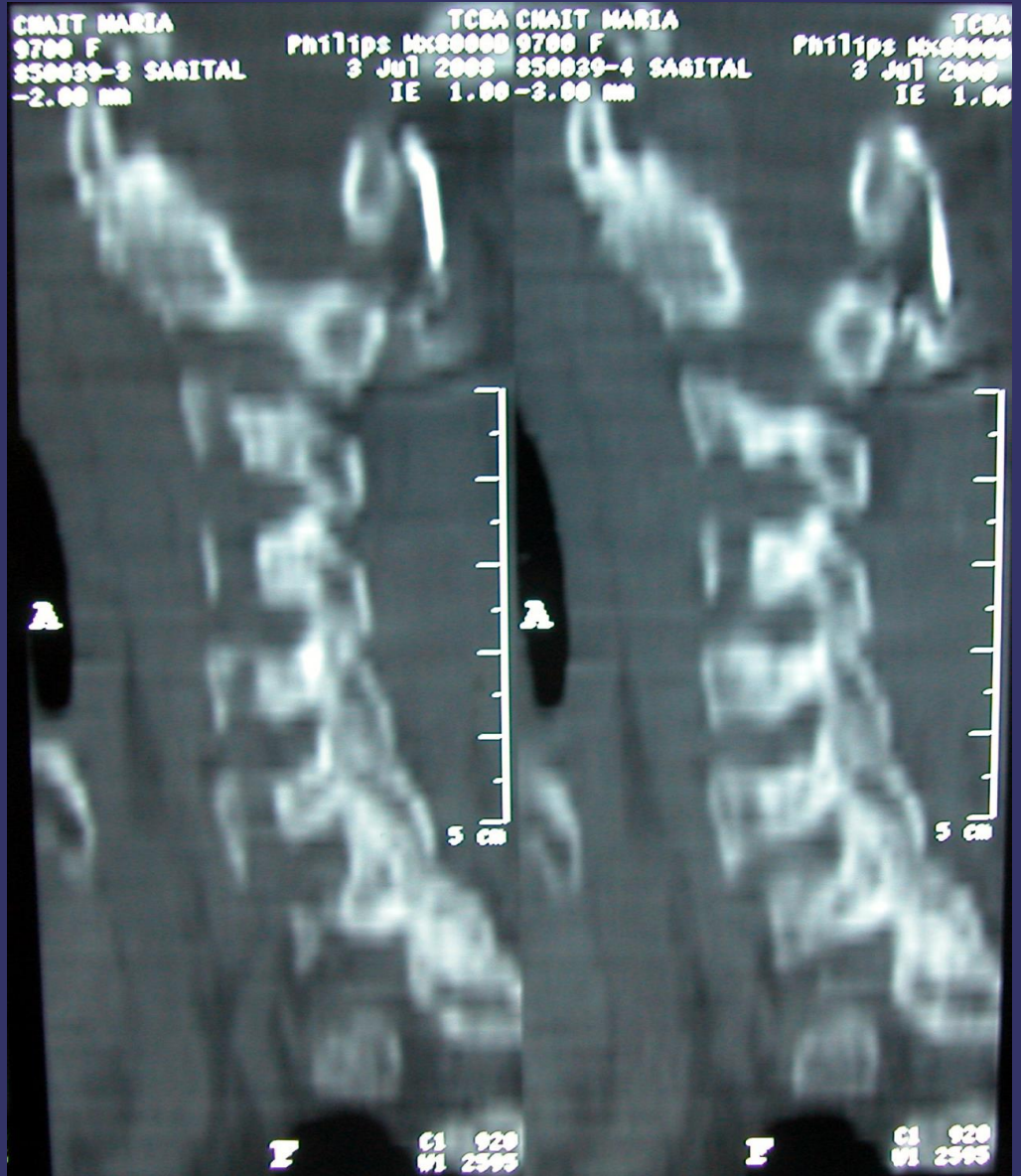
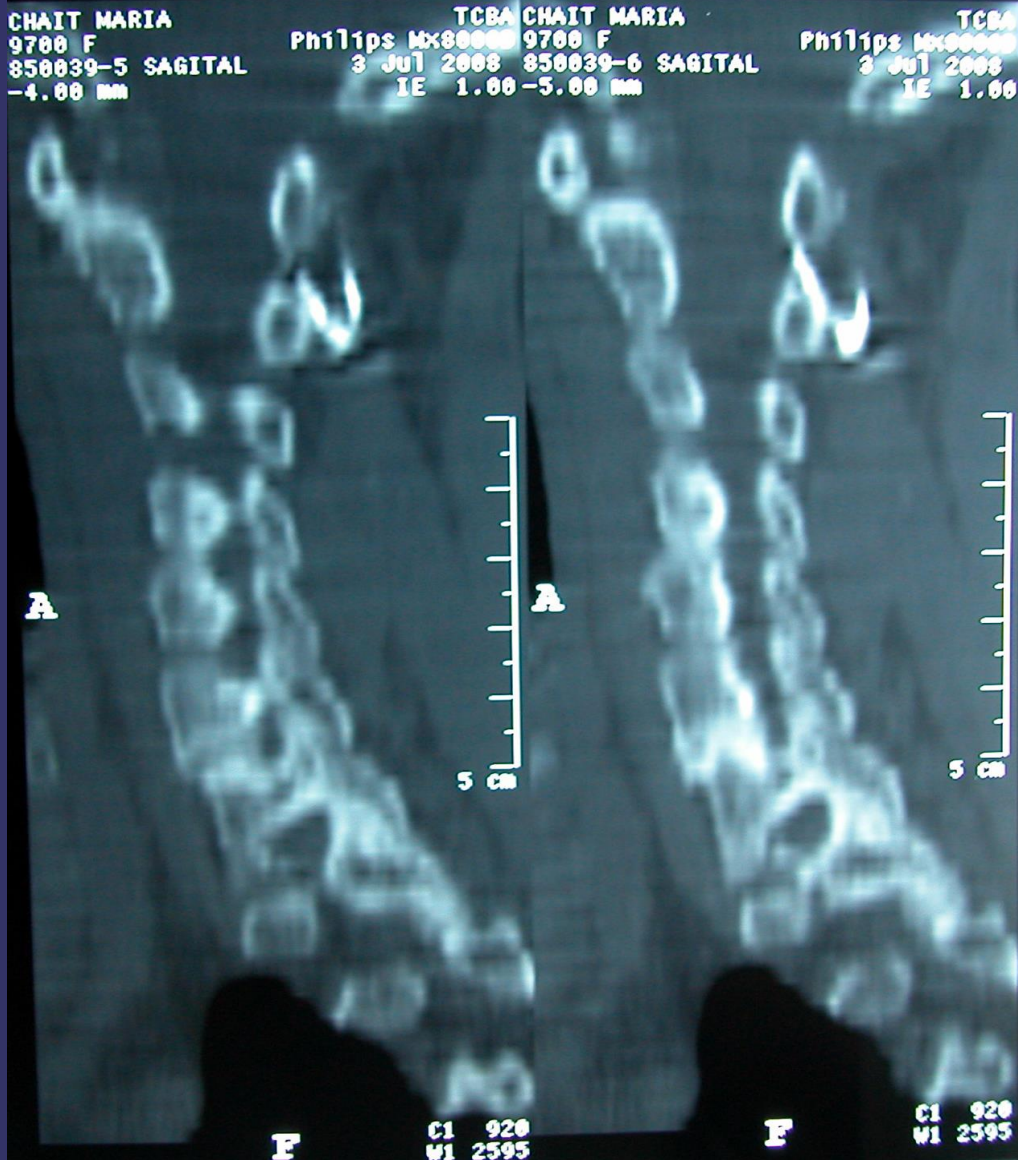





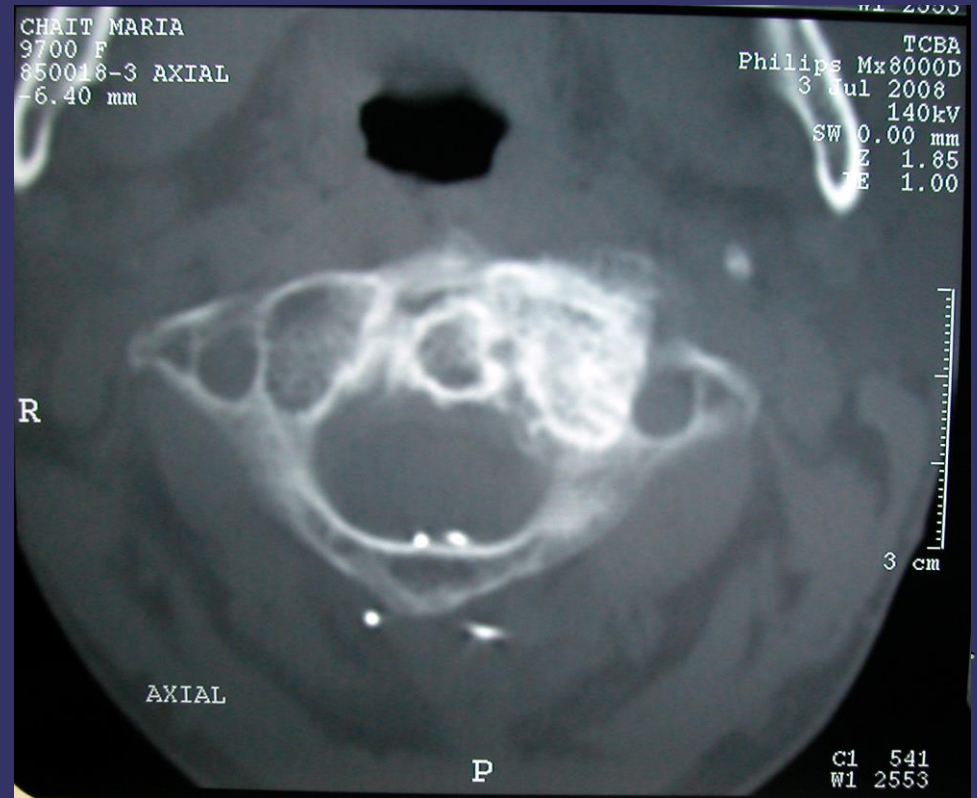
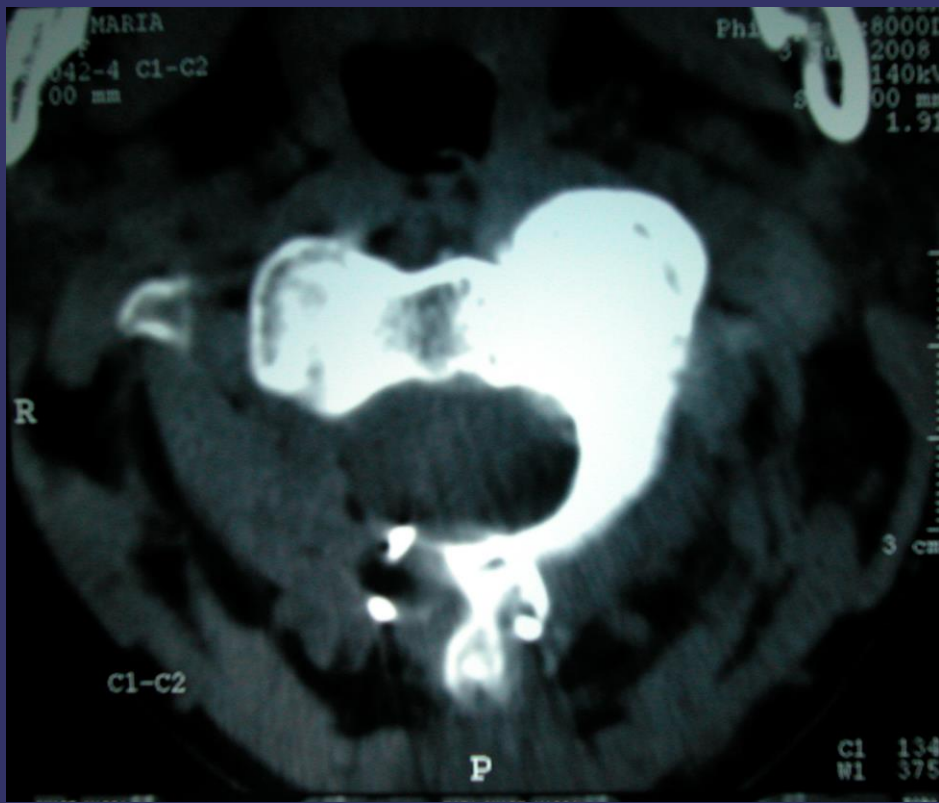







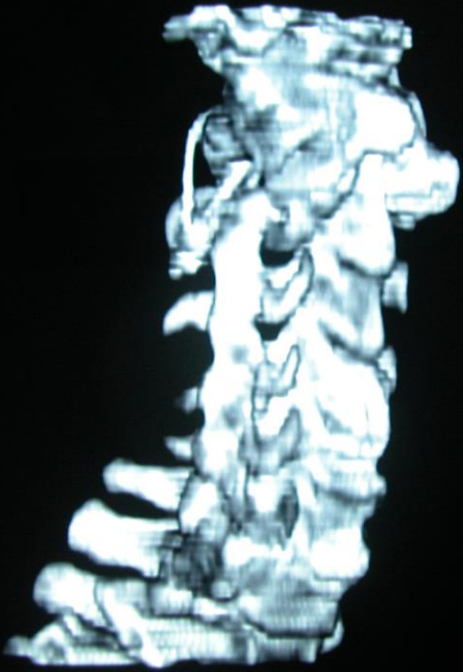CHAIT MARIA
9700 F
8500-6 3D

TCBA
Philips
3 Jul 2008
Z 1.71

PR

20 cm

R A



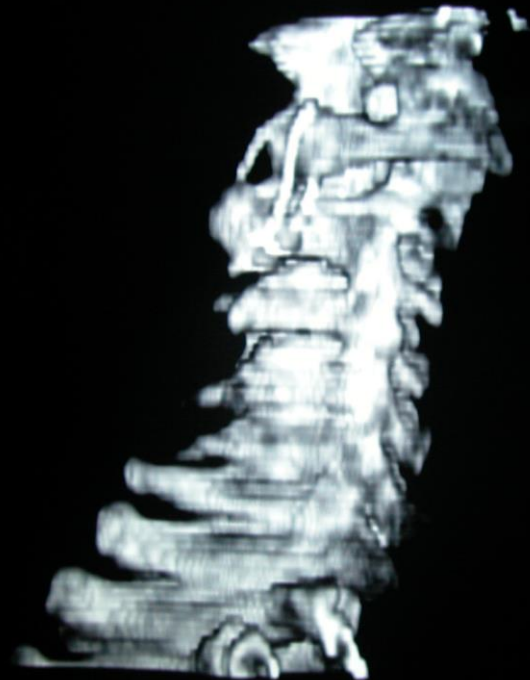CHAIT MARIA
9700 F
8500-5 3D

TCBA
Philips
3 Jul 2008
Z 1.71

PL

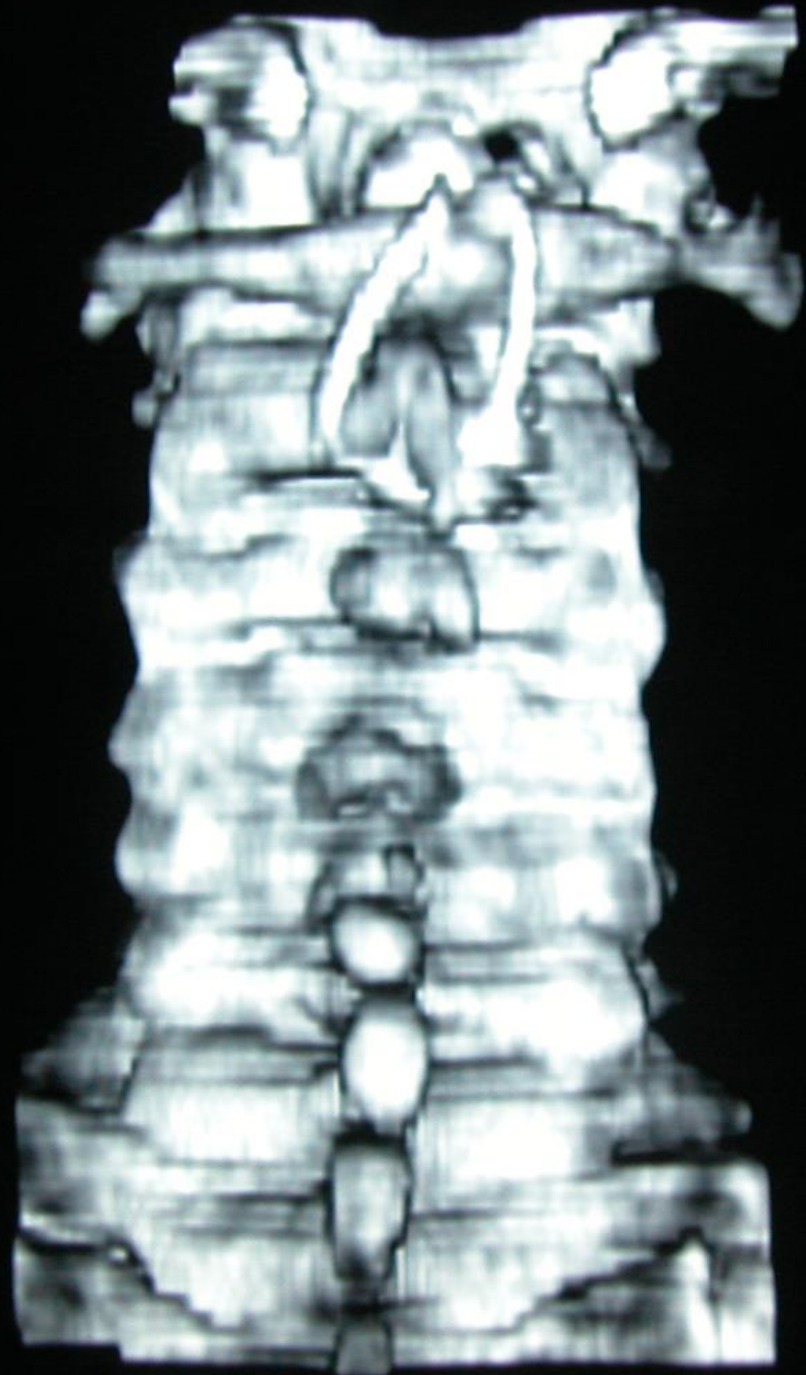
20 cm

P R

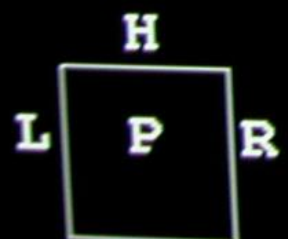

CHAIT MARIA
9700 F
8500-4 3D

TCEA
Philips
3 Jul 2008
Z 1.71

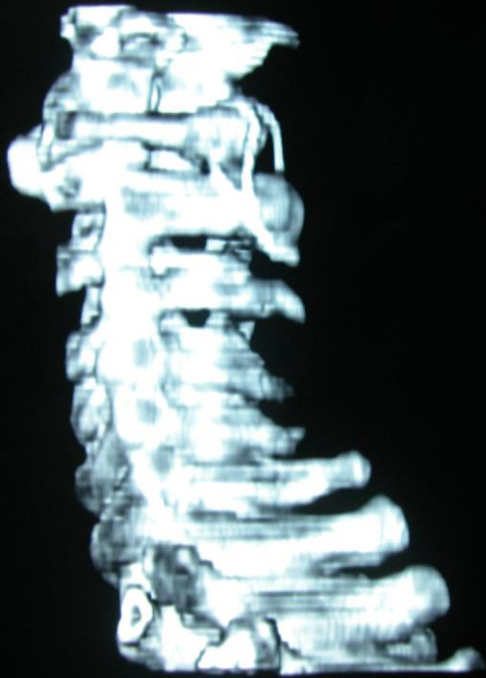


L



CHAIT MARIA
9700 F
8500-3 3D

TCEA
Philips
3 Jul 2008
Z 1.71



AL

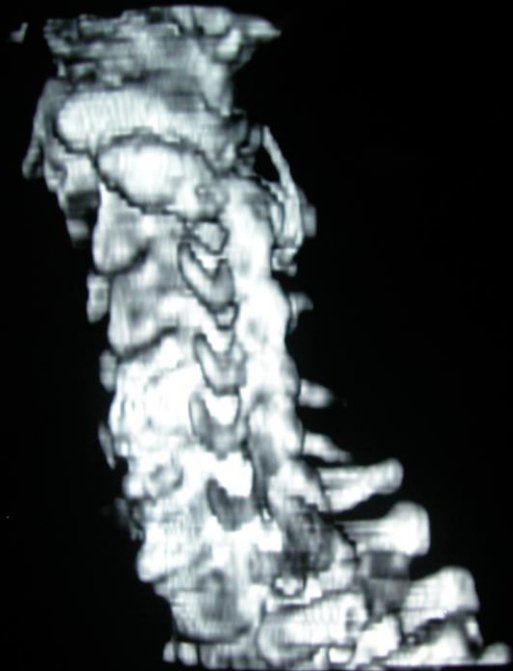20 cm

L

P

CHAIT MARIA
9700 F
8500-2 3D

Philips
3 Jul 2008
Z 1.71



AR

20 cm

A

L

Caso 2

- M 49a.
- Paraparesia 3/5 mayor a izquierda
- Hiperreflexia rotuliana y aquílea bilateral

